

S. Aboujaoude*, B. Noueiri*, R. Berbari*,
A. Khairalla**, E. Sfeir*

*Department of Pediatric Dentistry

**Department of Maxillofacial Radiology

FMD, Lebanese University

Faculty of Dental Medicine, Lebanese University, Beirut

e-mail: preliasfeir@gmail.com

dental arch for a certain period of time. In our study this technique yielded significant clinical improvements, but the radiological improvement is considered moderate. Future investigations are warranted in order to determine the possible effects of Pulpotec on the succedaneous teeth as well as their path of eruption.

Keywords Endodontic treatment; Furcation bone lesion; Necrotic primary molars; Path of eruption; Pulpotec.

Evaluation of a modified Pulpotec endodontic approach on necrotic primary molars: a one-year follow-up

ABSTRACT

Aim The aim of this study was to evaluate the effectiveness of a Pulpotec modified endodontic approach on primary molars presenting necrotic pulp and furcation bone loss in a cohort of healthy children.

Materials and methods Forty primary necrotic molars in healthy children, aged between 4 and 6 years underwent clinical and radiological assessment. A chemomechanical removal of pulpal necrotic debris was performed with 1% sodium hypochlorite irrigation. The canals were dried and Pulpotec was inserted in the pulp chamber, and the teeth were then restored. Clinical evaluation, vertical and horizontal measurements of the bone radiolucency were performed for up to one year after the Pulpotec procedure. Statistical analysis: Wilcoxon signed-rank test was applied for comparison of groups.

Results In this study 67.7% of patients showed healing of bone loss, and a significant difference in height and width of the lesion was observed (respectively 80.6%, 71%; $p < 0.05$; $p < 0.025$).

Conclusion This technique can be used as an alternative to conventional endodontic treatment for primary necrotic teeth. This procedure may allow paedodontists the ability to postpone extraction of necrotic teeth in particular situations or until eruption of the first permanent molar. Necrotic primary molars presenting furcation bone lesion due to infection may be treated with this modified Pulpotec procedure. With certain caveats, this procedure will preserve the molar on the

Introduction

The endodontic treatment of primary necrotic molars remains a challenging therapeutic problem for the paedodontist [Fuks, 1999]. In selected clinical situations, even with a poor prognosis, pulp treatment can be performed [Fuks, 1999; Ralph, et al., 2011]. Temporary teeth have a specific internal anatomy of the pulpal cavity presenting features that are not commonly observed in permanent teeth such as connections involving furcation and horizontal anastomoses [Aminabadi et al., 2008; Kielbessa et al., 2003]. The difficulty in shaping and filling the root canals of primary teeth, in addition to the problem of managing paediatric patients, leads many clinicians to avoid the pulpectomy technique [Koch and Poulsen, 2001]. Preserving the primary molar to avoid the use of a space maintainer, should be considered and can be justified [Thomas et al., 1994; Saziye and Zeynep 2008]. The success of an endodontic treatment on primary necrotic teeth depends on the difficulty of treatment, the microbial elimination in the root canal and periapical region [Srinivasan et al., 2006] and the biocompatibility of the filling material that can promote healing [Perinpanayagam, 2009].

Many reports on the use of different filling materials for pulpectomies of necrotic temporary teeth show great success (94 to 100%) [Sari and Okte, 2008; Mendoza et al., 2010; Mortazavi and Mosbahi, 2004]. On the other hand, filling materials containing iodoform became a material of choice in treating necrotic primary teeth [Morio et al., 2013; Mortazavi and Mosbahi, 2004; Shenkin 2012]. In the last decade, three novel approaches about the treatment of necrotic primary molars attracted our interest: Firstly, in the user instruction sheet of the Pulpotec pulpotomy treatment, the following statement was listed as indication for paedodontics: "treatment of infected deciduous molars by pulpotomy even in the presence of an abscess". Secondly, in 2011, Pinky et al. applied the concept of lesion sterilisation and tissue repair therapy (LSTR), a non-invasive approach, as a "pulpotomy-like" technique. During this procedure, the root canals are not cleaned, and only the pulp chamber and the root canals entry are filled with antibacterial materials. The authors reported a high level of success [Pinky et al., 2011]. Finally, Manisha et

al. [2011], noted clinical and radiological success in using the Pulpotec pulpotomy even on vital primary molars with partial necrosis or abscess [Manisha et al., 2011].

We decided to evaluate a new approach inspired from these three techniques and we evaluate the effectiveness of Pulpotec used as a dressing in the pulp chamber after cleaning and disinfection, with copious irrigation with 1% sodium hypochlorite of the root canal complex. This procedure was performed on primary molars presenting necrotic pulp and bone lesion.

Materials and methods

Forty primary molars were treated with “PD” Pulpotec (Produits Dentaires SA, Vevey, Switzerland) at the Paediatric Dentistry Department, School of Dentistry at the Lebanese University. Patients selected for the study were 24 boys and 16 girls aged between 4 and 6 years (mean age 5 years). The inclusion criteria were as follows.

1. Presence of necrotic pulp lesion.
2. Mobility independent from normal physiological exfoliation.
3. Pain on percussion.
4. Presence of fistula or furcation abscess.
5. Radiographic signs of bone lesion.
6. Absence of systemic diseases.
7. Restorable tooth

Kids with internal and lateral root resorptions or cystic lesion were excluded from this study.

A signed informed consent was obtained from all participants’ parents prior to enrolment in the study.

Clinical and radiological procedures:

Preoperative periapical radiographs of the selected teeth were performed using the Rhin system standard parallel technique. The same distance was applied between the film and the x-ray cone for all teeth. In the first 10 cases, a calibrated metallic ring (3 mm internal diameter, 7 mm

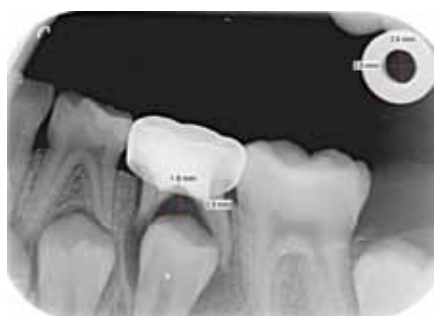

FIG. 1 Periapical x-ray showing vertical and horizontal measurements of the furcation bone loss on the second left lower primary molar.

external diameter) was positioned at the right upper corner of the film (Fig. 1). After rubber dam placement and complete removal of carious tissue, the pulp chamber was accessed and the necrotic pulp removed under irrigation using a steel round bur (# 021, Pegasus Dental supplies Ltd, Cheshire, England) with a low-speed handpiece. Following localisation of the root canal entry, the working length was estimated by periapical x-rays and was fixed at -1 mm from the radiological apex (American Academy of Pediatric Dentistry, 2009). Removal of pulpal debris from the root canals using files (Hedstrom files #15, 20 Mani, Yohara, Japan), and copious irrigation with 1% sodium hypochlorite were performed. The canals were dried with paper points (Sure-endo, Chevreuse, France).

Pulpotec was prepared following the manufacturer’s instructions; the mix was placed only in the pulp chamber and pressed with a plugger to ensure uniform adaptation to the pulp chamber. The cavity was filled with IRM (Caulk Dentsply, Milford, USA). The tooth was restored either with a stainless steel crown or a hermetic glass ionomer-composite filling. A periapical x-ray was taken using the same parameter of the pre-op x-ray. The entirety of the procedure was performed in a single visit. Since lesions have an irregular shape, measurements were taken on their central largest height and width. The measurements of radiolucency were applied using the direct proportional method, and were documented for each lesion. Afterwards the radiographic results were digitised and analysed using a specific software (VistaScan Mini Plus, Dürr Dental, Germany) measuring the furcation radiolucency.

Clinical and radiological follow-up

Patients were followed clinically every month for the first three months. After that, a clinical and radiological assessment was performed every 3 months over a one-year period. The treatment was considered successful if the teeth showed any or all of the following.

1. Absence of gingival swelling and redness.
2. Resolution of the pathological mobility.
3. Presence of healthy soft tissue.
4. Clinical healing of the fistula.
5. Decreasing of the size of the interradicular and/or periapical radiolucency.
6. Radiographic signs of bone regeneration.

At the follow-up time, four patients did not show up and five were excluded due to the loss of the stainless steel crown. For each of the remaining 31 patients, the largest height and width of the bone radiolucency measurements were performed both before and one year after treatment of the tooth (Table 1).

	Negative Ranks	Positive Ranks	Ties	Mean of Negative Ranks	Mean of Positive Ranks	Sum of Negative Ranks	Sum of Positive Ranks	Z	Asymp. Sig. (2-tailed)
vert_treat - vertical	25(a)	4(b)	2(c)	15.60	11.25	390.00	45.00	-3.732	0.000
hori_treat - horizontal	22(a)	8(b)	1(c)	17.43	10.19	383.50	81.50	-3.107	0.002

TABLE 1 the sum of positive and negative ranks in both axes (vertical and horizontal) and their respectively calculated z-statistic.

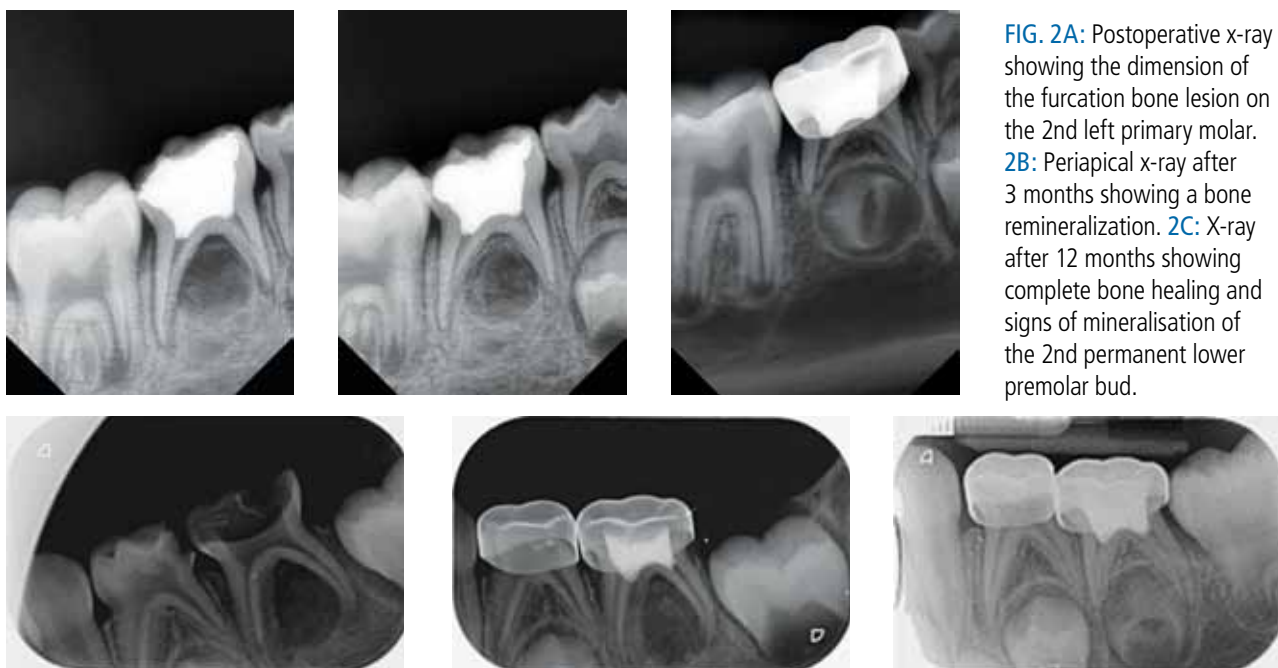


FIG. 2A: Postoperative x-ray showing the dimension of the furcation bone lesion on the 2nd left primary molar. **2B:** Periapical x-ray after 3 months showing a bone remineralization. **2C:** X-ray after 12 months showing complete bone healing and signs of mineralisation of the 2nd permanent lower premolar bud.

FIG. 3A: Preoperative periapical x-ray of a 2nd left primary molar showing an interradicular radiolucency. **3B:** 1 month after Pulpotec treatment. **3C:** X-ray taken after 12 months showing the complete healing of the lesion.

Results

The paired t-test and the Wilcoxon signed-rank test were used to compare continuous and categorical variables in this study. In order to assess the effectiveness of the treatment, the hypothesis tested was that the mean bone loss measurements after treatment had to be identical to the mean measurements before the treatment. Due to the parameters used, hypothesis testing was carried out twice: The first for height of bone loss measurements and the second for the width. About sixty-eight percent (67.7%) of the patients showed recovery of bone loss (Fig. 2, 3), both in height and width directions (80.6%, 71%) (Table 2). The pain, swelling and fistula disappeared in all except one case after one week. At the follow-up no clinical pathological signs were detected, even in teeth with radiological failure (that is those where radiological lesions remained unchanged) (Fig. 4).

Discussion

Mechanical root canal preparation alone cannot completely eliminate microorganisms from the root canals, but can help reduce the bacterial load and may promote bone healing [Parasuraman and Muljibhai, 2012]. Mechanical instrumentation and the use of NaClO to disinfect and clean the root canal system, reduce the bacterial load, and promote healing [Parasuraman and Muljibhai, 2012; Peters et al., 2001]. Infact the NaClO, by dissolving necrotic pulp, works as an efficient antiseptic [Tang et al., 2000; Vostatek et al., 2011]. On the other

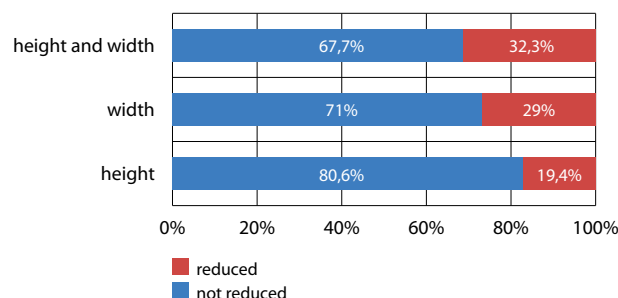


TABLE 2 Paired t test

hand, pulpectomy on necrotic temporary teeth and filling with material containing iodoform showed great success (94 to 100%) [Sari and Okte 2008; Splieth 2011; Mendoza et al., 2010; Mortazavi and Mesbahi 2004; Shenkin 2012]. The difficulty and the risk in shaping the root canal are the reasons why many paedodontist opt for extraction of the tooth. For this reason, in the clinical protocol we propose, cleaning of the necrotic content of root canals is performed under irrigation [NaClO] with files N. 15 and 20 only, which present no risk. This way the necrotic debris can be removed from the canal while disinfecting. This approach represents an advantage with respect to the LSTR technique. [Pinky et al., 2011] and avoid petrification of the necrotic pulp

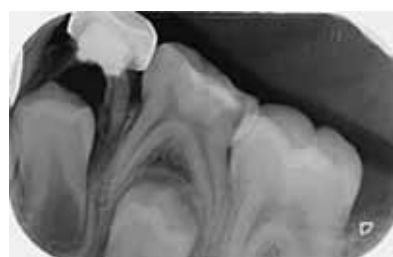

FIG. 4 A radiological failure with increase of the lesion after 1 year.

on the long term, which could be an irritating factor and therefore maintain a chronic inflammation. Thus, only the pulp chamber is filled by Pulpotec, as in the pulpotomy treatment and according to the technique proposed by Pinky et al. [2011], Manisha et al. [2011] and the instruction use sheet of Pulpotec. Pulpotec was selected as pulp chamber filling material based on its antiseptic, antibacterial and anti-inflammatory properties [Wang and Huang, 2004; Cerqueira et al., 2008; Milnes, 2006; Milnes, 2008; Kakarla et al., 2013]. The main component of this product is iodoform, and, due to its antiseptic properties, it acts like an antibiotic paste at the entry of the empty root canal. This may explain the resolution of fistulas and the long-term clinical success registered in the present study. This approach avoids technical risk when treating the canals of deciduous teeth whether for filling purposes or instrumental preparation [Sari and Okte, 2008; Splieth, 2011; Cerqueira et al., 2008]

The distance between the film and the cone was the same for all the cases. In the first 10 x-ray the metallic ring on the right top corner was used to calculate with precision the radiolucency measurements and avoid errors while using the direct proportional method. Then the same proportion was applied for the rest of the cases.

Several authors have set criteria for assessing the post-treatment healing of necrotic temporary teeth [Trairatvorakul and Chunlasikaiwan, 2008; Mendoza et al., 2010; Mortazavi and Mosbahi, 2004; Nadkarni and Damle, 2000; AAPD, 2009]. According to them, our results show a significant healing in height and width directions regarding the bone resorption, respectively ($p < 0.05$) and ($p < 0.025$) (Table 2) (Fig. 2, 3). The use of IRM, with its fast setting properties (5 min), isolates Pulpotec from the oral cavity and therefore allows for tooth preparation and placement of a stainless steel crown or a hermetic filling during the same session. The use of Pulpotec may reduce the clinical signs of infection, and preserve the tooth on the arch for a longer time as in the case before the eruption of the first permanent molar.

Conclusions

Additional prospective studies are necessary to validate the results of the current study. Within the limitations of this study, we can conclude the following.

1. Selected necrotic primary molars showing bone lesion may be treated with this modified Pulpotec procedure. This procedure may preserve the tooth on the dental arch for a longer time as in the case before the eruption of the first permanent molar.
2. The use of Pulpotec may reduce the clinical signs of infection, but the extent of the bone healing is not the same for all cases.
3. This approach may also help reduce extractions of primary teeth and result in better compliance with follow-up care.

4. This procedure is efficient, easy to use and resulted to be associated with a high clinical success rate.
5. The clinical and radiological results show that this procedure could be considered as an alternative to the conventional endodontic treatment for primary necrotic teeth in paediatric dentistry.

References

- › American Academy of Pediatric Dentistry. Guidelines on pulp therapy for primary and young permanent teeth. *Pediatr Dent* 2009; 31(6):179–186.
- › Aminabadi NA, Farahani RMZ, Gajan EB. Study of root canal accessibility in human primary molars. *J Oral Sci* 2008; 50:69-74.
- › Cerqueira DF, Mello-Moura AC, Santos EM, Guedes-Pinto AC. Cytotoxicity, histopathological, microbiological and clinical aspects of an endodontic iodoform-based paste used in pediatric dentistry: a review. *J Clin Pediatr Dent* 2008;32:105-110.
- › Fucks AB. Pulp therapy for the primary dentition. In Pinkham, *Pediatric Dentistry, Infancy through adolescence*. 3rd ed. WB Saunders: Philadelphia; 1999. p2, 350.
- › Kakarla P, Avula J, Mellela G, Bandi S, Anche S. Dental pulp response to collagen and pulpotec cement as pulpotomy agents in primary dentition: a histological study. *JCD* 2013; 16:434-438.
- › Kielbassa AM, Muller U, Munz I, Monting S. Clinical evaluation of the measuring accuracy of Root ZX in primary teeth. *Oral Surg Oral Med Oral Pathol Oral Radiol Endod* 2003;95:94-100.
- › Koch G, Poulsen S. Clinical approach. In: *Pediatric dentistry*. Munksgaard: Copenhagen; 2001. p. 220.
- › Manisha A, Usha Mohan D, Deepak V. A comparative evaluation of noninstrumentation endodontic techniques with conventional ZOE pulpectomy in deciduous molars: an in vivo study. *World J Dent* 2011; 2 (3):187-192.
- › Mendoza AM, Reina JE, Garcia-Godoy F. Evolution and prognosis of necrotic primary teeth after pulpectomy. *Am J Dent* 2010; 23:265-268.
- › Milnes AR. Is Formocresol obsolete? A fresh look at the evidence concerning safety issues. *Pediatr Dent* 2008; 30: 237-246.
- › Milnes AR. Persuasive evidence that formocresol use in pediatric dentistry is safe. *J Can Dent Assoc* 2006; 72:247-8.
- › Morio K, Takeo W, Tomoko K, Maki O, Yukari H, Tomohiro I, Takeki T. Sensitivity of human dental pulp cells to eighteen chemical agents used for endodontic treatments in dentistry. *Odontology* 2013; 101: 43-51.
- › Mortazavi M, Mesbahi M. Comparison of zinc oxide and eugenol, and Vitapex for root canal treatment of necrotic primary teeth. *Int J Paediatr Dent* 2004;14:417-424.
- › Nadkarni U, Damle SG. Comparative evaluation of calcium hydroxide and zinc oxide eugenol as root canal filling materials for primary molars: a clinical and radiographic study. *J Indian Soc Pedod Prev Dent* 2000; 18:1-10.
- › Parasuraman VR, Mujibhai BS. 3Mix in endodontics-an overview. *JDMS* 2012;3:36-45.
- › Perinpanayagam H. Cellular response to mineral trioxide aggregate root-end filling materials. *JCDA* 2009; 75: 369-372.
- › Peters OA, Laib A, Gohring TN, Barbakow F. Changes in root canal geometry after preparation assessed by high resolution computed tomography. *J Endod* 2001;27:1-6.
- › Pinky C, Shashibhushan KK, Subbareddy VV. Endodontic treatment of necrotic primary teeth using two different combinations of antibacterial drugs: an in vivo study. *J Indian Soc Pedod Prev Dent* 2011; 29:121-127.
- › Ralph E. McDonald, David R. Avery, Jeffrey A. In *Dentistry for the child and adolescent*. Ninth edition Mosby, St Louis, 2011, 343-365.
- › Sari S, Okte Z. Success rate of Sealapex in root canal treatment for primary teeth: 3-year follow-up. *Oral Surg Oral Med Oral Pathol Oral Radiol Endod* 2008; 105(4): 93-96.
- › Saziye S, Zeynep O. Success rate of Sealapex in root canal treatment for primary teeth: 3-year follow-up. *Oral Surg Oral Med Oral Pathol Oral Radiol Endod* 2008; 105:93-96.
- › Shenkin JD. Pulpectomy of necrotic primary teeth may be an effective tool in managing the primary dentition. *J Evid Based Dent Pract* 2012; 12:39-40.
- › Splieth CH. *Revolutions in pediatric dentistry*. Berlin: Quintessence; 2011. p 186-190.
- › Srinivasan V, Patchett CL, Waterhouse PJ. Is there life after Buckley's Formocresol? Part I. A narrative review of alternative interventions and materials. *Int J Pediatr Dent* 2006; 16:117-127.
- › Tang HM, Nordbo H, Bakland LK. Pulpal response to prolonged dentinal exposure to sodium hypochlorite. *Int Endod J* 2000; 33:505-8.
- › Thomas AM, Chandra S, Chandra S, Pandey RK. Elimination of infection in pulpectomized deciduous teeth: a short-term study using iodoform paste. *J Endod* 1994; 20: 233-5.
- › Trairatvorakul C, Chunlasikaiwan S. Success of pulpectomy with zinc oxide-eugenol vs calcium hydroxide/iodoform paste in primary molars: a clinical study. *Pediatr Dent* 2008; 4:303-307.
- › Vostatek SF, Kanellis MJ, Gasparoni KW, Gregorsok RL. Sodium hypochlorite pulpotomies in primary teeth: a retrospective assessment. *Pediatr Dent* 2011; 33:327-32.
- › Wang HH, Huang LJ. Effect of tinidazole-dexamethasone-iodoform paste on controlling endodontic interappointment emergencies. *Shanghai Kou Qiang Yi xue* 2004;13(3):222-3.