

# Upper Jaw Development After Lingual Laser Frenectomy and Myofunctional Therapy



L. De Simone<sup>1</sup>, D. Martinelli<sup>2</sup>, M. Tieri<sup>2</sup>,  
A. Monaco<sup>1</sup>, D. Tripodi<sup>2</sup>

<sup>1</sup>University of L'Aquila, L'Aquila, Italy

<sup>2</sup>University "G. d'Annunzio" Chieti-Pescara, Italy

Email: dottlucidesimone@gmail.com

DOI 10.23804/ejpd.2024.2143

## Abstract

**Aim** Over the years, the role of the lingual frenulum in the development of skeletal structures has been evaluated. However, the effect of short lingual frenulum treatment on bone structures is unclear. We need to investigate the effect of surgery and myofunctional therapy on maxillary development. This could be the rationale to establish an orthodontic interception protocol.

**Method** The case-control study was carried out in the Operative Unit of Pedodontics of the University Dental Clinic, at the Department of Medical, Oral and Biotechnological Sciences of the University of "G. D'Annunzio" Chieti-Pescara. The study population consisted in thirty children. The data were collected through anamnesis carried out by qualified health personnel before dental examination. Photos, frenulum length and cast measurements were taken. Student's t-test statistical analysis was used. Significance was ascertained based on the obtained P value of less than 0.01.

**Results** Patients who chosen surgical/logopaedic treatment formed Test group A. Control group B was composed of children who had chosen speech therapy only. We made a comparison of the data between them. Maximum mouth opening clinical parameter, intercanine width (C value) and perpendicular width from the vertex of the incisive papilla to the straight line passing through the cusp tips of the maxillary canines (A value) showed significant variation difference ( $p < 0,01$ ).

**Conclusions** The results confirmed the benefit of laser surgical treatment. The change in parameters related to the anterior palate region showed the power of frenectomy and myofunctional therapy in restoring the tongue's ability to stimulate bone development. The protocol adopted in the following study could be used in interceptive orthodontics. However, further studies are needed to evaluate the effects on the upper jaw over the long term that have higher sample numbers.

## Background

The lingual frenulum extends from the underside of the tongue to the floor of the mouth. It could present abnormalities of length, volume, consistency, and insertion. The small portion of tissue, which should have undergone apoptosis during embryonic development, could remain in the sublingual surface [Knox, 2010]. This situation can limit tongue movement and lead to several problems in speech articulation, breastfeeding, swallowing, teeth position, malformation, and head posture. Effects of tongue-tie has been discussed in the medical literature that reports prevalence 3-4% [Ferrés-Amat et al., 2017; Lisonek et al. 2018; Lauren et al. 2007; Ballard et al. 2002]. Hogan et al. estimate a percentage of 10,7%. Males seem to be more affected than female patients in a proportion ranging from 2:1 to 1,5:1 [Hogan et al.2005]. Short lingual frenulum is one of the most common midline congenital developmental malformations. The Academy of Breastfeeding Medicine defines it as a "sublingual frenulum which changes the appearance

**KEYWORDS** Ankyloglossia, Short lingual frenulum, Tongue tie, Speech disorders, Palatal development, Malocclusion, Preventive orthodontics, Frenectomy.

and/or function of the infant's tongue because of its decreased length, lack of elasticity or attachment too distal beneath the tongue or too close to or onto the gingival ridge" [Amir et al. 2006]. However, there are different classifications of tongue-tie so univocal diagnosis is not allowed. The Hazelbaker Assessment Tool for Lingual Frenulum Function (HATLFF) assesses frenulum anatomy and function and scores ankyloglossia. This diagnostic strategy use points to definite normal or impaired frenulum, summarised in Table 1. Coryllos assessment and Kotlow's assessment base the clinical diagnosis on location and attachment (Table 1). In all these cases, condition of restrictive lingual frenulum limits tongue mobility. The ankyloglossia condition prevents the tongue from protruding beyond the lower incisor teeth and makes breastfeeding difficult. Failure to breastfeed can cause long damage over time [De Simone et al. 2023]. In orthodontics, the abnormal attachment of the tongue may affect the bone development of the jaws, dental occlusion, and nasal breathing [Brożek-Mądry et al. 2021; Cenzato et al., 2021; Farronato et al., 2012; Lumbau et al., 2011; Monaco et al., 2023; Paglia, 2023] medical approach comprising surgery and physiotherapy of the lingual movements [Tripodi et al., 2021; Saccomanno et al., 2017]. To avoid post-operative complications, the treatment of choice is frenectomy technique in association with functional therapy [González Garrido et al., 2022]. The role of ankyloglossia on growth and development of stomatognathic system is the rationale to investigate the effect of therapy on palatal expansion.

## Methods

The scientific data do not have the power to clarify if the ankyloglossia can be considered a co factor in the development of dentofacial anomalies. The aim of this work is to investigate the effect of surgery and myofunctional therapy on maxillary development. This could be the rationale to establish a protocol to prevent malocclusion in toddlers.

### *Inclusion and exclusion criteria*

The case-control study was carried out in the Operative Unit of Pedodontics of the University Dental Clinic, at the Department of Medical, Oral and Biotechnological Sciences of the University of "G. D'Annunzio" Chieti-Pescara. This investigation was conducted in accordance with the ethical principles of the European Union rules on good clinical practice, according to the declaration of Helsinki and the additional requirements of

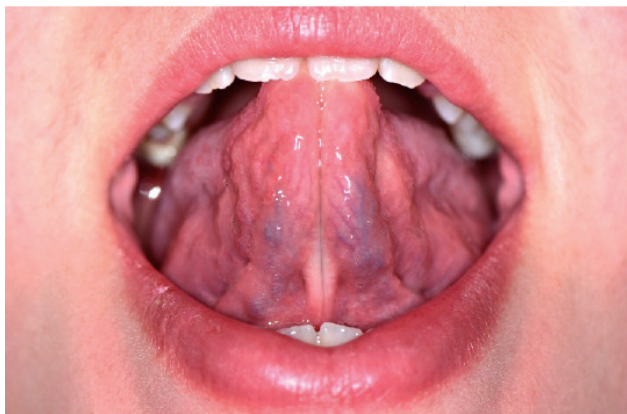

FIG. 1 The maximum opening of the mouth tongue spot

Italian law. Written consent was obtained from the parents of each toddler. The samples include fifteen patients, divided into test group A and control group B. The selection of patients in each group was based on the parents' choice to have the children undergo surgical/logopaedic treatment. The study was conducted for a period of six months. They are fourteen males and sixteen females, aged between 3 and 15 years. The mean age is  $8.85 \pm 3.02$  years. Patients with previous histories of frenectomies, orthodontic and maxilla-surgery treatments were excluded from this study. To evaluate palatal change, anatomical reference points are teeth 5.5, 6.5 and maxillary canines. Premature loss of this primary teeth is an exclusion criterion.

#### Study design

All children received a complete oral and lingual examination. The subjects were referred by their paediatricians or dentists. Standardised photos and clinical measurements were taken during all medical checks. Step by step, data collection was carried out by the same researcher. At the initial visit ankyloglossia was diagnosed based on the physical and functional characteristics. Speech therapy was a prerequisite to surgery for all patients. Toddlers were required to complete at least 1 month of preoperative and encouraged to follow - up with at least 6 months of postoperative myofunctional therapy. After laser frenectomy, the patient returned for 1-week, 1-month, 3-months and 6-months visits. Children had to remain compliant with speech

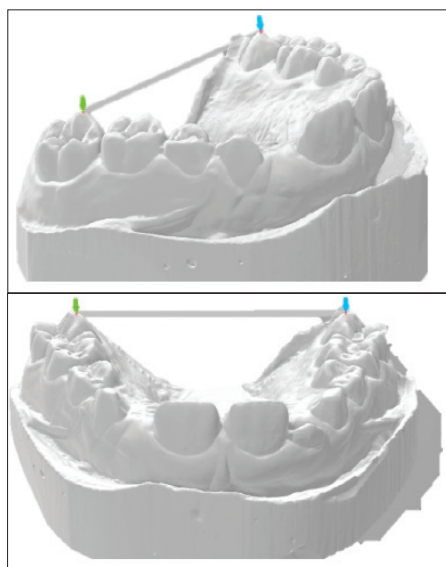


FIG. 2 The digital evaluation of plaster models

therapy to avoid relapses.

#### Measurement of frenulum length

The examination was done by the same professional health investigator. The length of the frenulum was measured by recording the distance between the insertion of the mucosal fold into oral floor to the tongue. It was carried out at maximum opening, trying to touch the palatal papilla with the tip of the tongue (Fig. 1). An indirect measurement was done by recording the distance between incisal margins of the upper central and the lower central incisor. Clinical evaluation was performed with a digital calliper, calibrated to at least tenths of a millimetre.

#### Measurements on cast

First impression for dental casts were obtained from the children, before the surgical treatment. The procedure was repeated after 1 week, 1 month, 3 months and 6 months. The alginate impressions were stored in a sealed plastic bag for up to 120 h and poured with type III dental stone.

To evaluate maxillary development, the measurement was directly performed from the cast by AutoScan DS-EX (SHINING 3D Tech Co., Ltd Hangzhou, China) and Blender Software (Blender Foundation) (Fig. 2).

The ratings were:

1. Intercanine width C (the gap from the cusp tip of canine to the other one) (Fig. 3);
2. Intermolar width M (the gap from mesiopalatal cusp tip maxillary first molar to the other one) (Fig. 3);
3. Perpendicular width from the vertex of the incisive papilla to the straight line passing through the cusp tips of the maxillary canines A (as Fig. 3);
4. Perpendicular width from the vertex of the incisive papilla to the straight line passing through mesiopalatal cusp tip maxillary first molar to the other one B (as Fig. 3);
5. Depth of the palate  $\Theta$  (the gap from the deepest point of the palatal vault to the gingival margins of the maxillary first molar) (Fig. 3).

#### Treatment Protocol- Surgical Procedure of Frenectomy

The authors treated patients with diode laser technique (G-laser 25, Galbiati S.r.L., Milan, Italy). Surgical purpose was used because of its safe and easy use. Local anesthesia was achieved by applying anaesthetic spray (Lidocaine spray, Ognà S.p.A. Milan, Italy) and infiltration of Articaine (Pierrel S.p.A, Milan, Italy). Pressure was applied lateral to the frenulum to locate the point of maximum tension. Frenulum was incised by applying 2 W of power. The Ga Al As diode laser device was used with a continuous wavelength of 810-890 nm. The dissection was continued until there was adequate improvement to the tongue range of motion. In fact, passively, the tongue is moved to assess whether it achieves physiological movement of 360 degrees. Care was taken not to affect any vascular tissue and small vessels are effectively coagulated. No suture was applied. No postoperative complications occurred, such as bleeding, blockage of Wharton's duct during suturing on the ventral surface of the tongue. A laser surgical purpose was used for its safety and easy use. However, in this case, the chances of complications are very rare.

#### Treatment Protocol—Myofunctional Therapy

Exercises are essential for a successful outcome. Performing the exercises before surgery was the necessary condition for continuing treatment. To evaluate compliance, young patients were asked to perform speech therapy exercises in front of the operator. They increase range of motion and prevent improper healing of post-

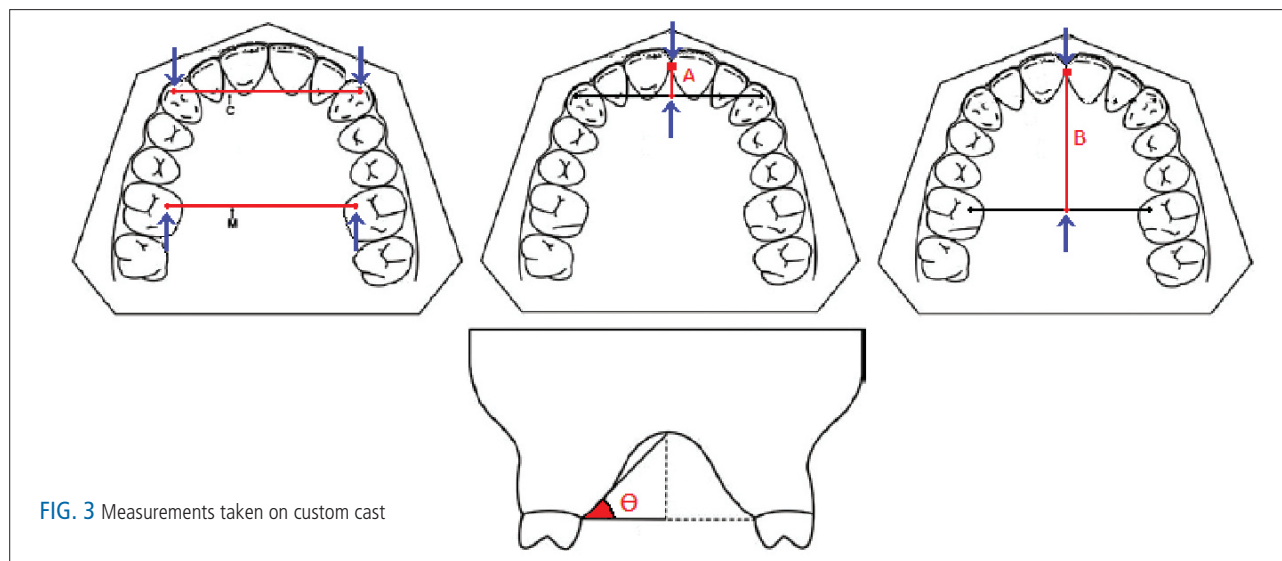


FIG. 3 Measurements taken on custom cast

surgical wounds. Normal swallow shows the positioning of the tongue high on the palate behind the maxillary incisors. In wrong position, the tongue gets thrust ahead to create cases of open bite. The type of movement is self-correcting with the eruption of primary dentition. Sometimes this is not possible because of short lingual frenulum. For optimal results, patients must do pre-operative and post-operative exercises at recommended frequency. Before surgery, the re-education of muscles lead compliance. The rehabilitate compensation patterns affects the postoperative recovery. Passive and active interventions were performed by a professional speech therapist. The logopaedic had the task of motivating the patient during all session.

Below are the exercises:

- Tongue-spot: the child is asked to open the mouth, hold the lower jaw down and locate the spot behind the upper incisors on the palate. Push as hard as possible for 20 seconds and repeat 10 times.
- Tongue-click: the child is asked to place the tongue against the roof of the palate (the spot) and snap it down. It makes a clicking or popping noise.
- Tongue around the world: the child is asked to move the tongue in a circle along the teeth, passing through the upper and lower arches. 10 for each direction.
- Touch-nose-chin exercises: the child is asked to protrude out the tongue and try to touch the nose and the chin.
- Touch-sideways movement exercises: the child is asked to protrude out the tongue and moving it in extreme right and left directions.
- Tongue-exercise using food reinforces sticky food can be placed either on the palate, the corner of the mouth, the lips, or the chin, thereby increasing the tongue increasing.
- Lip-lickers: licking lips in a circle, as if trying to lick away food.

For the first 20 days the exercises should be performed 3 times a day. Thereafter it is necessary to scale up the required frequency: after 20 days twice a day, after another 20 days once a day, then alternating every other day and finally twice a week. The goals are to create awareness of tongue posture and tone the muscles of the orofacial complex.

#### Statistical Analysis

The chosen samples had a normal distribution according to the Gauss curve. The averages of A group were compared with those

of control B group. Significance was ascertained from the P value obtained by Student's t-test statistical analysis. P values below 0.01 were considered statistically significant.

#### Results

In this study, 15 patients, 7 males and 8 females, were enrolled in the test group A. Control group B, on the other hand, consisted of 15 children with the same sex type as group B. The A group was characterised by patients who underwent laser lingual frenectomy surgery and were followed closely from a myofunctional point of view. While, in control group B, there were patients who, despite having a short lingual frenulum, did not want to undergo any surgery. They retained all related complications. For both A group and B group, the differences of the mean values of each parameter mentioned above were obtained for different time periods. The obtained averages of A group, then, were compared with control group B ones. The significance was ascertained from the P- value obtained by Student's t-test statistical analysis. The clinically recorded data were at the initial time 0, 1 week, 1 month, 3 months and 6 months. The maximum mouth opening parameter of the tongue-spot showed difference between groups significant variation (P value < 0.01). About measurement on casts, there is statistical significance for C value (intercanine width) and A value (perpendicular width from the vertex of the incisive papilla to the straight line passing through the cusp tips of the maxillary canines) between A and B groups. The mean changes assessed at 0, 1 week, 1 month, 3 months and 6 months (Table 1). M (intermolar width) and B value (perpendicular width from the vertex of the incisive papilla to the straight line passing through mesio-palatal cusp tip maxillary first molar to the other one) showed a lower degree of significance of variation with P value < 0.05 (Table 1).

#### Discussion

The impression was handled carefully to limit the possibility of stretching. Assessments on plaster casts are subject to bias, related to the limitations of the technique [Tomita et al., 2018]. Although, they are negligible because present for all measurements we compared each other. Oral habits also can interfere with the position of the teeth and with normal skeletal growth [Grippaudo et al., 2016]. Patients were advised to avoid damage behaviours. Major environmental factors include thumb sucking, nail biting, mouth breathing and atypical swallowing [Otsugu et al., 2023].



The outcome of the study is limited by children's behaviour, which could not be monitored. Regarding the parameter of A group test, the maximum opening of the tongue point (tip of the tongue in contact with the spot), had an average increase in each time. Comparison with control group B showed that the difference is not random ( $p$  value  $< 0,01$ ). In the graph, mean differences in mm and time intervals in steps were expressed. In Figure 4, the size increased overall except in the first week after surgery. This is probably related to the difficulty of managing wound discomfort, especially in young patients. However, improved lingual movement is the motivation for assessing the effect on palate development [Canadian Agency for Drugs and Technologies in Health, 2016]. The value of maximum mouth opening by having the tip of the tongue held in contact with the palatine papilla was statistically significant, confirming the therapeutic nature of the treatment [Meenakshi et al., 2014]. According to Moss's functional matrix theory, restored tongue function is the basis for the later results [Moss, 1981; Moss and Salentijn, 1969]. Functional matrices played a primary morphogenetic role. The restored movable muscle of the mouth has got an influence in the development of maxillary bone structures, in the same way that a normally functioning tongue. In the test group A, intercanine distance C increases significantly ( $P$ -value $<0.01$ ) in the period of the last 3 months, particularly in the interval between time 0 and 6 months. As can be seen in the line graph of Figure 4, the discrepancy between the test group and the control group is greatest in the last period. At first, the lack of benefit associated with frenectomy, and speech therapy may be justified by the fact that repeated actions on the tongue were necessary to achieve change (Fig. 4). There are several studies [Crippa et al., 2016; Garrocho-Rangel et al., 2019; Ghaheer et al., 2017; Olivi et al., 2012; Olivi et al., 2021] advocating surgical treatment of pathological lingual frenulum in order to increase lingual mobility and avert associated complications. In the study of P. Defabianis [2000], a patient was monitored clinically and radiologically for seven years to study changes in palatal structures after surgical therapy performed on the short lingual frenulum. For intermolar width M, although always increasing, the change is less important than for intercanine width. According to the results obtained in this study, the mean change in M, is never significant ( $P > 0,01$ ). The  $p$ -value in the last three months is  $< 0.05$ . Perhaps by increasing the study time, the difference between control group A and control group B could become statistically significant. By evaluating the perpendicular distance between the apex of the interincisive papilla and the line passing through the cusps of the canines of maxillary (A value), a statistically significant variation was found between test group to control group B. The  $P$  value was  $<0.01$  in both the time interval between 0 and 3 months and that between 0 and 6 months. In the line graph (Fig. 4) significant long-term rather than short-term variation can also be seen for this parameter. B-value assessed perpendicular width from the vertex of the incisive papilla to the straight line passing through mesioalatal cusp tip maxillary first molar to the other one and included A-value. According to the results obtained in this study, the B value varies in agreement with A, but in a statistically less significant manner. During the timeline, depth of the palate  $\theta$  didn't change in a statistical significance way ( $P$ -value  $> 0,05$ ). In all these cases, they lead to anatomical and functional improvement. No orthodontic treatment could be required as the tongue itself has achieved full function [Tepedino et al., 2022]. The following thesis is, moreover, supported by the results obtained from the 2017 study by Yoon et al. [2017]. Statistically significant growth of the anterior component of the palate three months after laser surgery increases at six months. This shows a tendency to continue with increasing variations in later times.

Maximum opening of the mouth tongue-spot		
	TEST GROUP A	TEST GROUP B
Time interval (mm)	Mean $\pm$ SD	Mean $\pm$ SD
1 WEEK-TIME O	4.11 $\pm$ 1.60	0.20 $\pm$ 0.23
1 MONTH - TIME O	5.74 $\pm$ 1.81	-0.16 $\pm$ 0.01
3 MONTHS - TIME O	7.35 $\pm$ 2.11	-0.2 $\pm$ 0.63
6 MONTHS -TIME O	8.64 $\pm$ 2.75	-0.23 $\pm$ 0.45
1 MONTH - 1WEEK	2.98 $\pm$ 2.31	-0.36 $\pm$ 0.24
3 MONTHS - 1 MONTH	1.16 $\pm$ 0.61	-0.04 $\pm$ 0.18
6 MONTHS - 3 MONTHS	1.29 $\pm$ 0.76	-0.03 $\pm$ 0.22
Intercanine width C		
	TEST GROUP A	TEST GROUP B
Time interval (mm)	Mean $\pm$ SD	Mean $\pm$ SD
1 WEEK-TIME O	0.14 $\pm$ 0.10	0.14 $\pm$ 0.01
1 MONTH - TIME O	0.27 $\pm$ 0.09	0.20 $\pm$ 0.16
3 MONTHS - TIME O	0.56 $\pm$ 0.18	0.43 $\pm$ 0.25
6 MONTHS -TIME O	1.34 $\pm$ 0.26	0.37 $\pm$ 0.06
A value		
	TEST GROUP A	TEST GROUP B
Time interval (mm)	Mean $\pm$ SD	Mean $\pm$ SD
1 WEEK-TIME O	0.11 $\pm$ 0.07	-0.22 $\pm$ 0.13
1 MONTH - TIME O	0.41 $\pm$ 0.18	0.21 $\pm$ 0.12
3 MONTHS - TIME O	0.65 $\pm$ 0.29	-0.13 $\pm$ 0.04
6 MONTHS -TIME O	0.86 $\pm$ 0.36	-0.01 $\pm$ 0.09
B value		
	TEST GROUP A	TEST GROUP B
Time interval (mm)	Mean $\pm$ SD	Mean $\pm$ SD
1 WEEK-TIME O	0.02 $\pm$ 0.05	-0.09 $\pm$ 0.03
1 MONTH - TIME O	0.43 $\pm$ 0.21	0.01 $\pm$ 0.001
1MONTH-IWEEK	0.32 $\pm$ 0.16	0.10 $\pm$ 0.02
3 MONTHS - TIME O	0.69 $\pm$ 0.33	-0.27 $\pm$ 0.15
3 MONTHS - 1 MONTH	0.23 $\pm$ 0.10	-0.28 $\pm$ 0.09
6 MONTHS -TIME O	0.78 $\pm$ 0.17	-0.16 $\pm$ 0.11
6 MONTHS - 3 MONTHS	-0.51 $\pm$ 0.31	0.11 $\pm$ 0.13

TAB. 1

## Conclusion

The results obtained through measurements taken during follow-ups confirmed the benefit of laser surgical treatment in combination with myofunctional therapy. In agreement with the results of this study, postoperative variation in the parameters near the palatine spot showed a greater change than in posterior sector. It seems that tongue-tie treatment could prevent the wrong forward-palatine development. If treatment is needed that does not involve the anterior area, it would still be appropriate to use orthodontic devices. Therefore, it would be desirable to continue this work by increasing the number of samples and follow-up time. Further studies are needed to assess the influence on post-palatine development. Orthodontic interception would reduce the cost of dental treatment and promote spontaneous and harmonious bone development.

## References

- Amir LH, James JP, Donath SM. Reliability of the hazelbaker assessment tool for lingual frenulum function. *Int Breastfeed J.* 2006 Mar 9;1(1):3. doi: 10.1186/1746-4358-1-3.
- Ballard JL, Auer CE, Khoury JC. Ankyloglossia: assessment, incidence, and effect of frenuloplasty on the breastfeeding dyad. *Pediatrics.* 2002 Nov;110(5):e63. doi: 10.1542/peds.110.5.e63. PMID: 12415069.
- Brožek-Mádry E, Burska Z, Steć Z, Burghard M, Krzeski A. Short lingual frenulum and head-forward posture in children with the risk of obstructive sleep apnea. *Int J Pediatr Otorhinolaryngol.* 2021 May;144:110699. doi: 10.1016/j.ijporl.2021.110699. Epub 2021 Mar 29. PMID: 33823467.
- Cenzato N, Iannotti L, Maspero C. Open bite and atypical swallowing: orthodontic treatment, speech therapy or both? A literature review. *Eur J Paediatr Dent.* 2021 Dec;22(4):286-290. doi: 10.23804/ejpd.2021.22.04.5. PMID: 35034464.
- Crippa R, Paglia M, Ferrante F, Ottonello A, Angiero F. Tongue-tie assessment: clinical aspects and a new

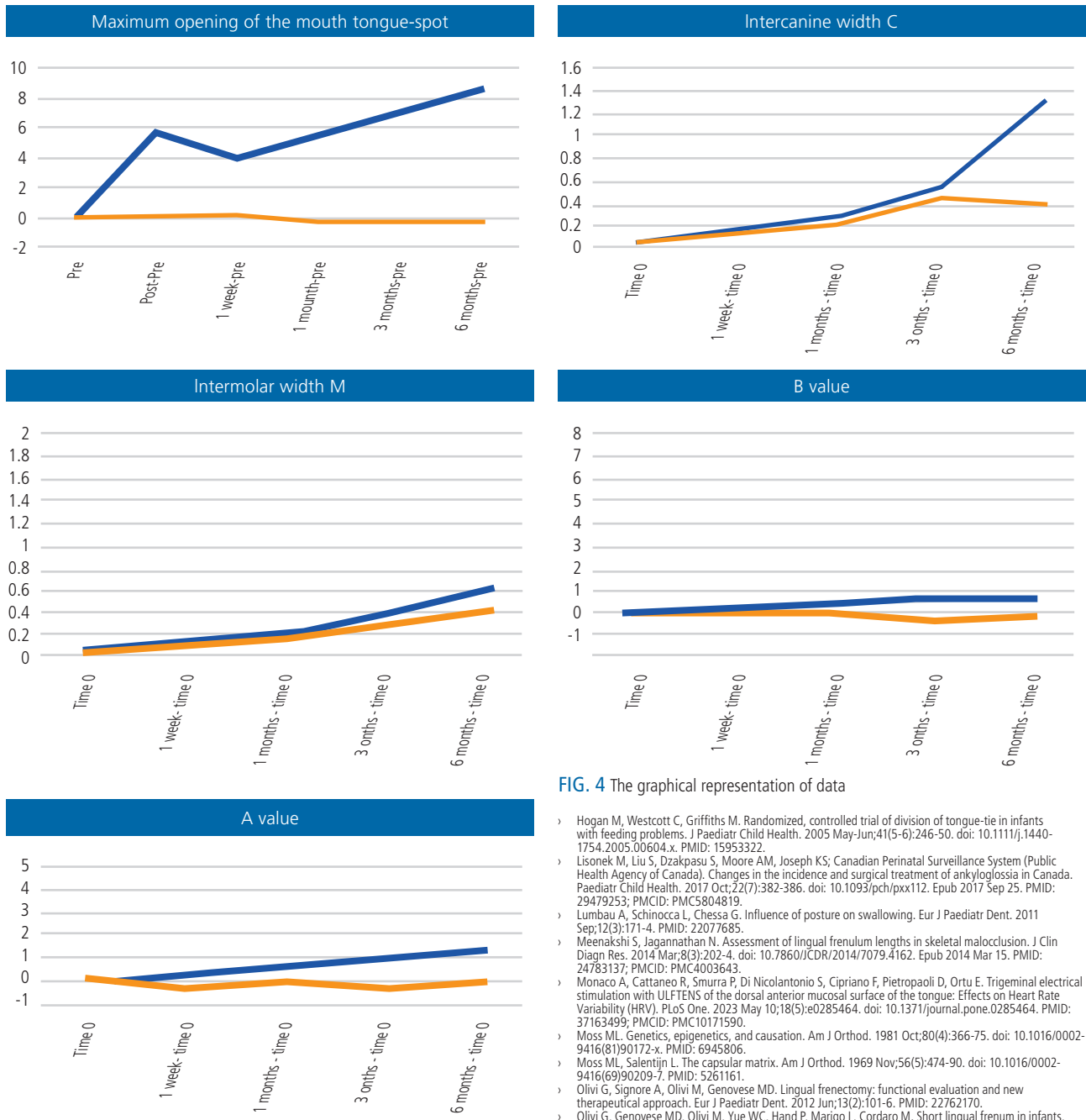

FIG. 4 The graphical representation of data

diode laser technique for its management. *Eur J Paediatr Dent.* 2016 Sep;17(3):220-222. PMID: 27759411.

Defabianis P. Ankyloglossia and its influence on maxillary and mandibular development. (A seven year follow-up case report). *Funct Orthod.* 2000 Oct-Dec;17(4):25-33. PMID: 11307269.

De Simone L, Ortu E, Barone A, Giannoni M, Pietropaoli D, Monaco A. AMASI epidemiological study on children living in L'Aquila. *Eur J Paediatr Dent.* 2023 Feb;24(1):49-55. doi: 10.23804/ejpd.2023.24.01.09. PMID: 36853213.

Farronato G, Giannini L, Riva R, Galbiati G, Maspero C. Correlations between malocclusions and dyslalias. *Eur J Paediatr Dent.* 2012 Mar;13(1):13-8. PMID: 22455522.

Ferrés-Amat E, Pastor-Vera T, Rodríguez-Alessi P, Ferrés-Amat E, Mareque-Bueno J, Ferrés-Padró E. The prevalence of ankyloglossia in 302 newborns with breastfeeding problems and sucking difficulties in Barcelona: a descriptive study. *Eur J Paediatr Dent.* 2017 Dec;18(4):319-325. doi: 10.23804/ejpd.2017.18.04.10. PMID: 29380619.

Knox I. Tongue tie and frenotomy in the breastfeeding newborn. *Neo Rev.* 2010;11:513-519.

Garrocho-Rangel A, Herrera-Badillo D, Pérez-Alfaro I, Fierro-Serna V, Pozos-Guillén A. Treatment of ankyloglossia with dental laser in paediatric patients: Scoping review and a case report. *Eur J Paediatr Dent.* 2019 Jun;20(2):155-163. doi: 10.23804/ejpd.2019.20.02.15. PMID: 31246095.

Ghaheri BA, Cole M, Mace JC. Revision Lingual Frenotomy Improves Patient-Reported Breastfeeding Outcomes: A Prospective Cohort Study. *J Hum Lact.* 2018 Aug;34(3):566-574. doi: 10.1177/0890334418775624. Epub 2018 May 22. PMID: 29787680.

González Garrido MDP, García-Munoz C, Rodríguez-Huguet M, Martín-Vega FJ, Gonzalez-Medina G, Vinolo-Gil MJ. Effectiveness of Myofunctional Therapy in Ankyloglossia: A Systematic Review. *Int J Environ Res Public Health.* 2022 Sep 28;19(19):12347. doi: 10.3390/ijerph191912347. PMID: 36231647; PMCID: PMC9566693.

Grippaudo C, Paolantonio EG, Antonini G, Saule R, La Torre G, Deli R. Association between oral habits, mouth breathing and malocclusion. *Acta Otorinolaryngol Ital.* 2016 Oct;36(5):386-394. doi: 10.14639/0392-100X-770. PMID: 27958599; PMCID: PMC5225794.

Lingual frenotomy: Pre and post-operative exercises. *Tooth & Co Pediatric dentistry.* Available from: <https://www.toothandco.com/lingual-preop-exercises>.

Hogan M, Westcott C, Griffiths M. Randomized, controlled trial of division of tongue-tie in infants with feeding problems. *J Paediatr Child Health.* 2005 May-Jun;41(5-6):246-50. doi: 10.1111/j.1440-1754.2005.00604.x. PMID: 15953322.

Lisonek M, Liu S, Dzakpasu S, Moore AM, Joseph KS; Canadian Perinatal Surveillance System (Public Health Agency of Canada). Changes in the incidence and surgical treatment of ankyloglossia in Canada. *Paediatr Child Health.* 2017 Oct;22(7):382-386. doi: 10.1093/pch/pxx112. Epub 2017 Sep 25. PMID: 29479253; PMCID: PMC5804819.

Lumbau A, Schinocca L, Chessa G. Influence of posture on swallowing. *Eur J Paediatr Dent.* 2011 Sep;12(3):171-4. PMID: 22077685.

Meenakshi S, Jagannathan N. Assessment of lingual frenulum lengths in skeletal malocclusion. *J Clin Diagn Res.* 2014 Mar;8(3):202-4. doi: 10.7860/JCDR/2014/7079.4162. Epub 2014 Mar 15. PMID: 24783137; PMCID: PMC4003643.

Monaco A, Cattaneo R, Smurra P, Di Nicolantonio S, Cipriano F, Pietropaoli D, Ortu E. Trigeminal electrical stimulation with ULTFENS of the dorsal anterior mucosal surface of the tongue: Effects on Heart Rate Variability (HRV). *PLoS One.* 2023 May 10;18(5):e0285464. doi: 10.1371/journal.pone.0285464. PMID: 37163499; PMCID: PMC10171590.

Moss ML. Genetics, epigenetics, and causation. *Am J Orthod.* 1981 Oct;80(4):366-75. doi: 10.1016/0002-9416(81)90172-x. PMID: 6945806.

Moss ML, Salentijn L. The capsular matrix. *Am J Orthod.* 1969 Nov;56(5):474-90. doi: 10.1016/0002-9416(69)90209-7. PMID: 5261161.

Olivi G, Signore A, Olivi M, Genovese MD. Lingual frenectomy: functional evaluation and new therapeutical approach. *Eur J Paediatr Dent.* 2012 Jun;13(2):101-6. PMID: 22762170.

Olivi G, Genovese MD, Olivi M, Yue WC, Hand P, Marigo L, Cordaro M. Short lingual frenum in infants, children and adolescents. Part 2: Lingual frenum release. Functional surgical approach. *Eur J Paediatr Dent.* 2021;22(1):47-54. doi: 10.23804/ejpd.2021.22.01.09. PMID: 33719483.

Otsugu M, Sasaki Y, Mikasa Y, Kadono M, Sasaki H, Kato T, Nakano K. Incompetent lip seal and nail biting as risk factors for malocclusion in Japanese preschool children aged 3-6 years. *BMC Pediatr.* 2023 Oct 26;23(1):532. doi: 10.1186/s12887-023-04366-7. PMID: 37884943; PMCID: PMC10601139.

Paglia L. Interceptive orthodontics: awareness and prevention is the first cure. *Eur J Paediatr Dent.* 2023 Feb;24(1):5. doi: 10.23804/ejpd.2023.24.01.01. PMID: 36853207.

Pompéia LE, Ilinsky RS, Ortolani CLF, Faltin K Júnior. Ankyloglossia and its influence on growth and development of the stomatognathic system. *Rev Paul Pediatr.* 2017 Apr-Jun;35(2):216-221. doi: 10.1590/1984-0462/2017;35;2;00016. PMID: 28977337; PMCID: PMC5496731.

Saccomanno S, Di Tullio A, D'Alatri L, Grippaudo C. Proposal for a myofunctional therapy protocol in case of altered lingual frenulum. A pilot study. *Eur J Paediatr Dent.* 2019 Mar;20(1):67-72. doi: 10.23804/ejpd.2019.20.01.13. PMID: 30919648.

Segal LM, Stephenson R, Dawes M, Feldman P. Prevalence, diagnosis, and treatment of ankyloglossia: methodologic review. *Can Fam Physician.* 2007 Jun;53(6):1027-33. PMID: 17872781; PMCID: PMC1949218.

Tepeдино M, Esposito R, Montaruli G, Monaco A, Chimenti C, Ciavarella D. Changes in hyoid bone and tongue position in Class I subjects after orthodontic treatment with rapid palatal expander. *Cranio.* 2022 Sep 13:1-10. doi: 10.1080/08869634.2022.2121015. Epub ahead of print. PMID: 36101967.

Tomita Y, Uechi J, Konno M, Sasamoto S, Iijima M, Mizoguchi I. Accuracy of digital models generated by conventional impression/plaster-model methods and intraoral scanning. *Dent Mater J.* 2018 Jul 29;37(4):628-633. doi: 10.4012/dmj.2017-208. Epub 2018 Apr 17. PMID: 29669951.

Tripodi D, Cacciagrano G, D'Ercole S, Piccari F, Maiolo A, Tieri M. Short lingual frenulum: From diagnosis to laser and speech-language therapy. *Eur J Paediatr Dent.* 2021;22(1):71-74. doi: 10.23804/ejpd.2021.22.01.13. PMID: 33719487.

Yoon AJ, Zaghi S, Ha S, Law CS, Guilleminault C, Liu SY. Ankyloglossia as a risk factor for maxillary hypoplasia and soft palate elongation: A functional - morphological study. *Orthod Craniofac Res.* 2017 Nov;20(4):237-244. doi: 10.1111/ocr.12206. Epub 2017 Oct 10. PMID: 28994495.