Nasal bone modification compared to normal growth after rapid maxillary expansion anchored onto deciduous teeth: a CBCT retrospective study

M. Rosa[1], G. Manti[2], P. Lucchi[3], S. Mutinelli[3]

[1] University of Padua and Milan, Italy
[2] Private Practice, Trento, Italy
[3] University of Padua, Italy

DOI 10.23804/ejpd.2024.2330

email: giuseppemanti@marcorosa.it

Abstract

Introduction The present study was designed to evaluate the enlargement of the nasal bone as side effect when a treatment with a Haas rapid maxillary expander is performed in early mixed dentition.

Methods The CBCT imaging of 36 children (mean age 8,4; SD,1,5) were retrospectively selected and then traced in order to evaluate the change in the nasal bone (primary outcome) and in the maxilla (secondary outcome). Five distances and one angle were measured: upper and lower nasal bone width (UNBw and LNBw) as well as its inclination (NBi), and the maxillary bone at the level of infraorbital foramen (IOFw), the nasolacrimal duct (NLDd), and greater palatine foramina (PFd). The sample was divided in a treatment group (26 subjects; 14 males; 12 females; mean age 8,0; SD 0,9), comprising children who underwent to a rapid maxillary expansion, and a control group (10 subjects; 7 males; 3 females; mean age 9,3; SD 2,3) including untreated children homogeneous for dental age to the treated subjects. Measurements were performed at baseline or before the treatment (T0), and after 2 years (T1).

Results All measurements showed a significant change during the observation period with a similar trend in both groups: the transversal width of the nose and of the maxilla increased, while the nose inclination lowered. At the maxillary level, the total amount of change was significantly higher in the treated patients, while the variation in the nasal area reached the same magnitude in both groups.

Conclusion The transversal modification induced with a rapid maxillary expansion was limited to the maxilla without involving the nasal bones when the treatment was performed in early mixed dentition. The changes recorded in the nasal bones seem to be the same of what happens during normal growth.

KEYWORDS Rapid maxillary expansion, Early mixed dentition, Nasal bone enlargement, Skeletal growth, cone-beam computed tomography.

Introduction and background

Rapid Maxillary Expansion (RME) is a wide used clinical procedure aiming to correct a transversal maxillary deficiency and to increase its arch perimeter when anterior crowding is present. Its effectiveness has been confirmed as well in patients treated in early mixed dentition when the anchorage was moved from the permanent molars to the deciduous teeth, i.e. deciduous canines and second molars [da Silva Filho et. al., 1995; Rosa et al., 2016; Ugolini et al., 2015; Mutinelli and Cozzani, 2015; Rosa et al., 2012; Cozzani et al., 1999; Rosa, 2023; Longlax et al., 2020]. However, a clinical question is still open about the occurrence of nasal bone enlargement as a negative side effect following a rapid maxillary expansion treatment. Regarding the effect of the appliance onto maxillary bone structure, Wertz showed in his experiments onto dry skulls, that the sutures were opened in a triangular shape both in the palatal and in the nasal areas [1970]. In detail, from the frontal view the vertex of the triangle was located at the level of the nasal bone and the base in premaxilla area. At the same time, another triangle was visible from the occlusal view, with the vertex in the posterior palate and the base in the premaxilla. Those changes could lead to the thesis that the effect onto the naso-zigomatic suture could induce an enlargement of the nasal bone together with an increase in the nasal width and volume. In fact, Cameron et al. [2002], confirmed that the initial deficiency in latero-orbitale recorded in a group of patients was eliminated after the treatment with a rapid maxillary expander was performed.

As a consequence, from one side this increase in nasal volume could be considered beneficial for the patients, since it could positively affect breathing [Niu et al., 2020]. On the other hand, this enlargement of nasal bone width could change the facial aesthetics when it becomes visible. In fact, a permanent anatomical change of this bone could be triggered by the rapid maxillary expansion, even more when performed at an early stage when the maxilla-facial structures and sutures are maturing [Niu et al., 2020; Cross and McDonald, et al., 2000; Lione et al., 2013]. Even though several studies have attempted to investigate the modification produced by the RME onto the nasal structure in general [Wertz, 1970; Cameron et al., 2002; Cross and McDonald, et al., 2000; Timms et al., 1982; Garrocho-Rangel et al., 2023] those were not focused onto the orthopedic change affecting the nasal bone.

Thus, this study set out to examine the anatomical enlargement of the nasal bone at the end of the retention period in a group of children, who underwent to a rapid maxillary expansion carried out at an early stage of the mixed dentition. To test the hypothesis that rapid maxillary expansion does not widen the nasal bone,

we retrospectively analysed the cone-beam computed tomography (CBCT) imaging of 36 treated and untreated children collected from the archive of a private orthodontic practice.

Materials and Methods

A CBCT scan imaging of 36 children (mean age 8.4; SD 1.5) were collected from the archive of a private orthodontist (MR) and retrospectively evaluated. Each record was selected in sequence among the individuals who had received the radiologic exam in the time period from January 2014 to December 2018. After that exam, part of patients received a treatment with a palatal expander (treatment group, or TG: 26 subjects; 14 males; 12 females; mean age 8.0; SD 0.9) and the other individuals did not undergo any kind of orthodontic therapy (control group, or CG: 10 subjects; 7 males; 3 females; mean age 9.3; SD 2.3) including untreated children homogeneous for dental age to the treated subjects. In detail, the CBCT investigation of the maxilla was administered to the control group to diagnose impaired ears-nose-throat (ENT) conditions. Then, all the subjects were radiologically monitored again at the end of retention period in the TG or at two-year follow-up in the CG. As a standard protocol, all the individuals signed a written informed consent to the diagnostic and therapeutical procedures as well as permission to use their anonymised data for research purposes. In addition, the trial was performed in accordance with the Declaration of Helsinki.

Inclusion criteria

The inclusion criteria for all the participants were as follows: full erupted permanent maxillary central incisors and first permanent molars, healthy maxillary second deciduous molars and deciduous canines with one third maximum of root resorption, absence of reported or recorded previous orthodontic treatment, and finally lack of facial skeletal anomalies and/or syndromes. The CBCT-imagines at baseline (T0) either the end of retention period or at 2-year follow-up (T1) had to be available for all the patients. Furthermore, subjects who had received an additional orthodontic treatment during the observation period were excluded. Another inclusion criterion exclusively for the individuals of the TG was the clinical indication for starting the treatment with a rapid maxillary expander. In fact, those subjects had to show either one or both of the following conditions: a posterior unilateral or bilateral cross bite in first permanent molars region, and an evident maxillary incisor crowding at the dental stage when maxillary lateral incisors were absent or not fully erupted. In order to define "evident" the incisor's crowding, the available space for the lateral incisors in the dental arch must be at least 4 mm smaller than the M-D crown's dimension of the lateral incisors measured on the CBCT. Consequentially, the last inclusion criterion for TG was a minimum of 8 mm active expansion needed to correct the orthodontic problem (posterior cross-bite and/or crowding of the upper incisors).

Appliance description and treatment protocol

All patients of TG received a modified Haas RME (Rapid Maxillary Expander). The appliance was composed by a palatal screw (13 mm, Leone® A0620-13, Sesto Fiorentino, Italy) and two acrylic shields designed to adhering to the mucosa of the palatal vault (Fig.1). The distal arms of the screw were soldered on two stain steel bands (Leone® Calibra, Sesto Fiorentino, Italy) to be cemented on the second deciduous molars, while the two anterior arms to be bonded on the palatal surface of the deciduous canines. Two acrylic shields designed to adhering to the mucosa of the palatal vault not beyond the second deciduous molars, were built to the right and left of the screw aimed to reduce the relapse of basal bone expansion in the months following active expansion. The screw exerted 0.20 mm expansion by each activation (1/5 of a turn). All the appliances were manufactured by the same lab (Orthocheck, Trento, Italy). The RME was cemented on the deciduous molars using Transbond Plus Lite Cure Band Adhesive (3M Unitek, Monrovia, CA, USA) in accordance with the manufacturer's instructions. The anterior arms of the screw were bonded with light-cured composite (Synergy D6, Coltene, Switzerland) on the palatal surface of the upper deciduous canines. Before bonding the appliance, the deciduous canines were ground and etched, in order to facilitate the best possible adaptation of the screw's anterior arms to the deciduous teeth. The activation protocol included one turn twice a day (1/5 turn) in all patients of the study group. In average the patients received 51 (SD, 6) activations equivalent to 10.2 mm in screw enlargement. Occlusal selective grinding was also carried out occlusally on the deciduous molars and lower canines, to optimise the occlusal contacts of permanent molars. The procedure was stopped when the posterior cross-bite on first permanent molar was corrected as well as an adequate alignment-space for the lateral incisors was achieved. After that, the screw was locked with a stainless-steel ligature. The expander was kept in situ as a passive retainer for at least 12 months and in any case until upper lateral incisors had fully erupted as well as a stable, spontaneous adjustment in occlusion of the first permanent molars was obtained.

Outcomes, exposures and measurement procedure

Our primary outcome is the skeletal change in nasal bone area. This was estimated combining two linear distances or the variables Upper Nasal Bone width (UNBw), and Lower Nasal Bone width (LNBw) together with one angular measurement or the variable Nasal Bone inclination (NBi). Then, our secondary outcome i.e. the modification of the maxillary bone was evaluated analysing three linear distances between two symmetrical right and left anatomical structures: the Nasolacrimal Duct distance (NLDd), the Infraorbital Foramen distance (IOFd), and the Greater Platine Foramen distance (PFd). The linear and angular parameters were measured in millimeters and degrees, respectively. In addition, the subjects were categorised in two subgroups based on the administration or not of the treatment (primary exposure). Therefore, patients who received a treatment with a rapid maxillary expander were included in the treatment group (TG) and those, who did not in the control group (CG). The data were collected measuring the CBCT scans taken at baseline (T0), and again at appliance removal in TG and at the first follow-up in CG (T1). The radiologic procedure implied the usage of CBCT scan (Instrumentarium OP300, Maxio, Kavo 3D eXam, Biberach Germany) and the patient in orthostatic position. In addition, a vertical and horizontal sighting beam was employed aiming to make the head positioning accurate and repeatable in all examinations. In according to the principle of radiation safety "As Low As Reasonably Achievable" (ALARA: https://www.cdc.gov/nceh/radiation/alara.html), the ultra-low dose 3D imaging protocol was followed including as well an adjusted field of view (FOV, 8x8cm to limited to the maxillary complex, 1.17 sec, Voxel 0.3 mm, 90kV, 1.17 mAs, DAP:72μGy/s). Only one expert orthodontist (GM), traced and measured all CBCT images. The operator processed the DICOM files using Horos Software (OsiriX Medical Imaging Software, Geneva, Switzerland). In detail, multi-planar-reconstructions (MPR) were used at a slice thickness of 0.3 mm to measure upper and lower nasal bone as well as

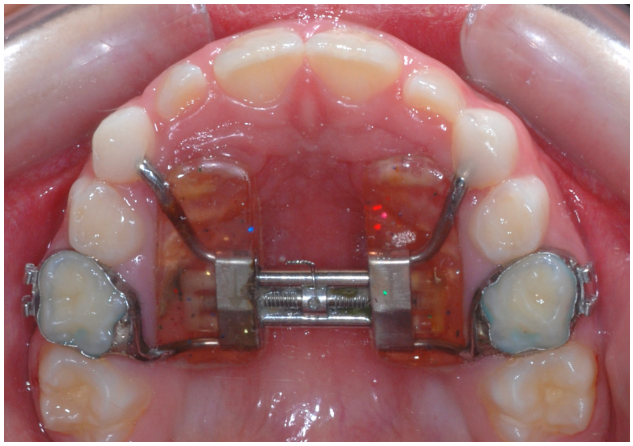

FIG. 1 Modified Haas RME.

its inclination, and the maxillary bone at the level of infraorbital foramen, the naso-lacrimal duct and greater palatine foramina. Each bone was simultaneously displayed in three windows in order to facilitate the operator to visualise the landmarks in the tomographic cuts. Every single window reveled the bone imagine respectively in the sagittal, axial and coronal-anatomical planes. Then, the operator had to select the reference plane and search the two landmarks of interest. If necessary, to better visualise the second foramen, it was helpful to move the reference axes. These axes were visible on each window as follows: purple/blu in the sagittal plane, blue/orange in the axial plane, and purple/orange in the coronal plane (Fig.2). Linear and angular measurements have been drawn in red.

Landmark definition, description and positioning on the Multi-Planar-Reconstructions

Upper Nasal Bone Width

The upper nasal bone width (UNBw) was measured 2 mm below the frontonasal suture on the coronal plane. The measurement was assessed between the most lateral margins of the nasal bones identified at the intersection with the fronto-nasal suture (Fig.3).

Lower Nasal Bone Width

The width of the lower nasal bone (LNBw) was measured as the distance between the maximally inferior and external border of the nasal bone placed in the coronal plane. At first, the sutures between the nasal bones and the frontal process of the maxillary bones were identified on both right and left side in a 3D image using the MIP (Max Intensity Projection) function. (Fig.4) This function is a volume rendering technique to obtain images, which preserve attenuation information independently of thresholds selected and has been largely employed in visualising maxillary skeletal structures [Ho et al., 2020; Mazziotti et al., 2015; Gribel et al., 2011; Fernandes et al., 2014]. After having visualised the lower-posterior edge of the nasal bones, the MIP function was disabled to allow the measurement on most reliable 2D slice. At this point, the distance between the lower and outer edges of the nasal bone was measured on the coronal plane (Fig.5).

Nasal Bone Inclination

The nasal bone inclination (NBi) was assessed onto the frontal plane as the angle located at the fronto-nasal suture. The two lines, which generate the angle, are the tangent to the frontal

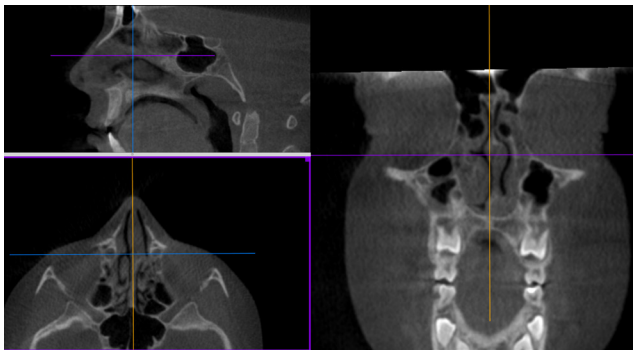

FIG. 2 References Axes.

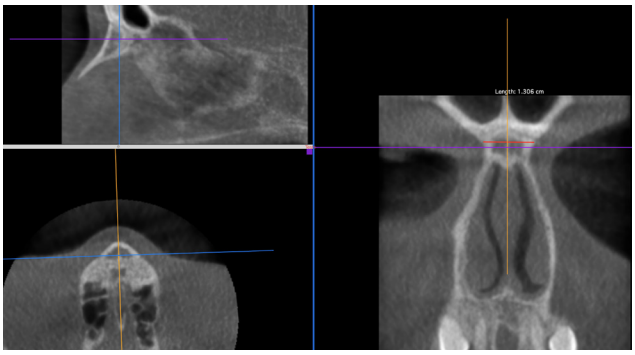

FIG. 3 Upper nasal bone width.

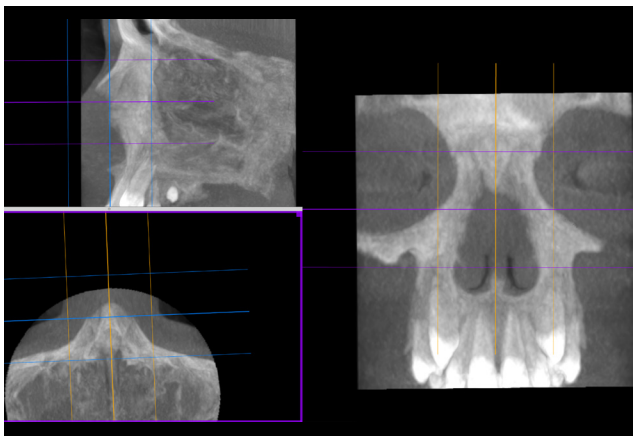

FIG. 4 3D MIP Lower nasal bone width.

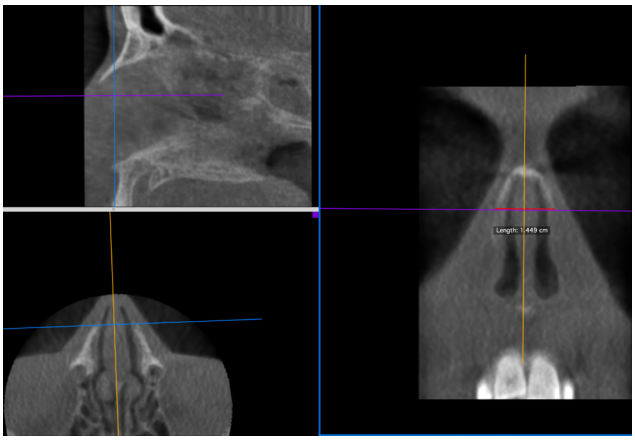

FIG. 5 2D Lower nasal bone widht.

bone passing through the fronto-nasal suture and the line connecting the same suture and the point identified at suture junction of lower anterior limit of the nasal bone. This angle defines the projection of the nasal bone tip (Fig.6).

Nasolacrimal Duct distance

The naso-lacrimal duct distance (NLDd) was measured on the axial plane between the geometric center of the upper circumference of each duct. This geometric center was identified viewing the naso-lacrimal ducts on coronal and axial planes (Fig.7). Then, using the coronal plane, the axis was placed on the correspondence of naso-lacrimal ducts. Finally, the distance between the right and left ducts has been measured on the axial plane from the points corresponding to the geometric center of the upper circumference.

Infraorbital Foramina distance

Infraorbital foramen distance (IOFd) is the distance between the two foramina and was measured onto the axial plane. The infraorbital foramina were individuated scrolling the slice in the caudal direction on the axial plane and in a forward direction on the coronal plane (Fig.8). The distance between the right and left foramen was measured on the axial plane.

Palatal Foramen distance

The greater palatine foramen distance (PFd) was measured onto the axial plane. The width was obtained as the distance between the geometric center of right and left palatine foramina (Fig.9).

Statistical Analysis

The primary outcome, or skeletal change of nasal bone, results from the combination of three variables (UNw, LNw and NBi) measured as the difference of the value recorded at baseline or before the treatment (T0) and that one at the end of retention or at 2-year follow-up (T1). The secondary outcome, i.e. the transversal skeletal change of the maxilla, was estimated in a similar way as the difference of the three variables, or NLDd, IOFd, and PFd measured at the same time point T0 and T1. All the variables are continuous and were tested for normality. The primary exposure consisted in the categorical variable "group", which includes two levels corresponding to the administration (TG) or not (CG) of a rapid maxillary expansion treatment.

The comparison at baseline between TG and CG was performed running a t-test for independent data when the variables were normally distributed (variables: LNBw, NLDd and PFd; Shapiro-Wilk test, $P > 0.05$) and using the Mann-Whitney test in case of absence of normality (variables: UNBw, IOFd and NBi; Shapiro-Wilk test, $P < 0.05$).

The change between the variables measured at the two time points within each group was analysed with t-test for dependent data and Wilcoxon signed-rank test. The size effect of the two groups was compared using the two-sample t test and the Mann-Whitney test. The t-tests for dependent and independent measures were run for normally distributed data, and the other

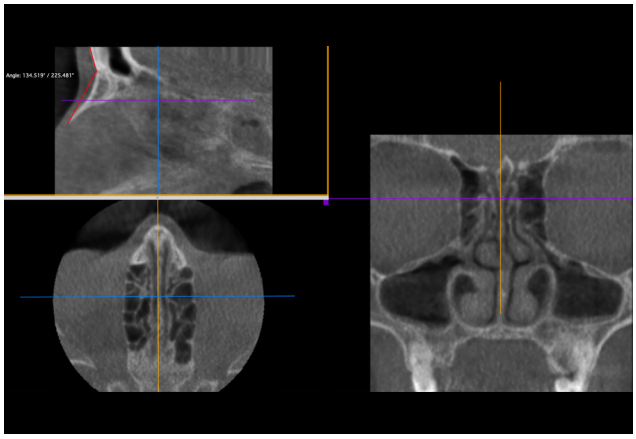

FIG. 6 Nasal bone angle.

FIG. 7 Naso-lacrimal duct distance.

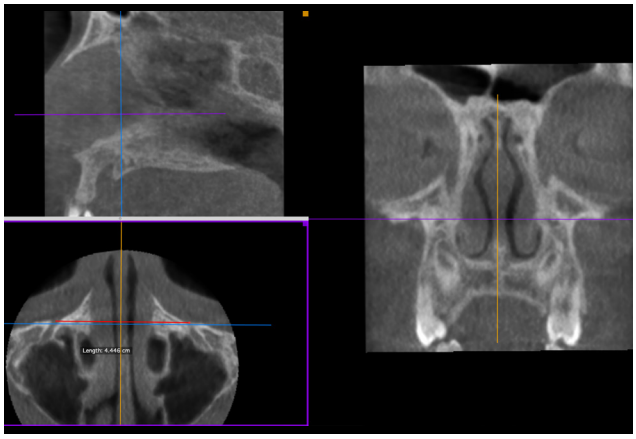

FIG. 8 Infra-orbital foramina distance.

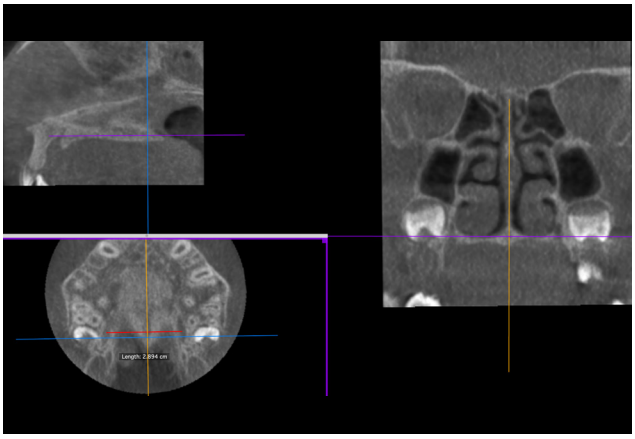

FIG. 9 Palatal foramen distance.

	Treatment Group (N=26)	Control Group (N=10)	Comparison between groups
Cephalometric parameter			P- value†
SNGoGn			
mean (SD*), degrees	34.2 (4.2)	33.5 (4.7)	0.6595
FMA			
mean (SD*), degrees	25.5 (3.1)	24.5 (3.9)	0.4409
SNA			
mean (SD*), degrees	80.7 (3.1)	79.9 (2.2)	0.4385
SNB			
mean (SD*), degrees	77.2 (3.4)	77.5 (3.6)	0.8074
ANB			
mean (SD*), degrees	3.5 (2.4)	2.1 (3.1)	0.1552

The two groups were homogeneous for all cephalometric variables at baseline. (P > 0.05; T-test for independent data)
** SD is Standard Deviation*
† T-test for independent data.

TABLE 1 Descriptive statistics (mean and SD) of the cephalometric parameters in TG and CG at baseline (T0).

two tests if the assumption of normality had been violated. The alpha-level was fixed at P = 0.05. All data was analysed with Stata package 14.2 (StataCorp, College Station, Tex).

The sample size was estimated a priori assuming a mean difference of the primary outcome (change from T0 to T1 in TG and CG) of 2.0 millimeters or degrees (t-test for independent data; SD, 1.0; alpha-level, 0.05; power of the test 90%), which was a value hypothesised as visible and noticeable, and hence clinically relevant. It followed, that the total sample size needed amounted to 14 patients.

The method error was calculated by means of Dahlberg's formula, comparing 30 measures collected twice in a subsample of patients including the first 5 individuals of the dataset at a one-week interval. The result obtained amounted to 0.087 and was consistent with a reliable method.

Results

Sample description

Out of 36 CBCT imagines, 26 belonged to patients treated with a rapid maxillary expander in early mixed dentition (treated group, TG; 12 females and 14 males; mean age 8y; SD 0.9mo), and 10 to patients monitored for other orthodontic reasons and at the same dental stage of the treated group (control group, CG; 3 females and 7 males; mean age 9.3y; SD 2.3 y). Individuals of TG underwent to CBCT scan in average 4.5 mo (SD 6.6 mo) before the start of the treatment.The cephalometric measurement of the two groups has been displayed in table 1. The distribution of dental class among subjects was as follow: for the TG, 13 patients in class 1, 11 patients in class 2 and 2 patients in class 3; and for the CG, 4 patients in class 1, 4 patients in class 2 and 2 patients in class 3. In detail, the dental class 1 was defined when the upper deciduous canines were touching both the deciduous canine and the first deciduous molar of the mandibular arch.

The CBCT scan was repeated after 2,5y (SD 5.1mo) in the TG when the appliance was removed. This time interval included both the active expansion and the retention time. Also the CG received CBCT scan as check-up 2.9 y after the first exam at baseline (SD 5.1mo).

Primary and secondary outcomes

At baseline, the cephalometric parameters regarding the skeletal class and the divergence showed a non-significant difference between TG and CG (Table 1) as well as the other

	Treatment Group (N=26)		T0 vs T1	Control Group (N=10)		T0 vs T1
Skeletal parameters	Value at T0	Value at T1	P value	Value at T0	Value at T1	P-value
Upper Nasal Bone Width, UNBw						
median (Iqr*), mm	10.8 (2.3)	11.8 (3.0)	<0.001†	11 (3.3)	12.1 (4.1)	0.0033†
Lower Nasal Bone Width, LNBw						
mean (SD‡), mm	13.9 (1.4)	15.1 (1.5)	< 0.001§	14.3 (1.7)	15.4 (1.9)	0.0001§
Nasal Bone Inclination, NBi						
median (Iqr*), degrees	140.63 (4.3)	138.8 (3.7)	<0.001†	139.4 (4.9)	137.4 (4.4)	0.0033†
Naso Lacrimal Duct distance, NLDd						
mean (SD‡), mm	23.3 (1.4)	25.1 (1.6)	< 0.001§	23.7 (1.5)	24.7 (1.6)	< 0.001§
Infra-Orbital Foramen distance, IOFd						
median (Iqr*), mm	44 (2.4)	48.4 (3.4)	<0.001†	45.1 (4.3)	48.2 (5.1)	0.0033†
Palatal Foramen distance, PFd						
mean (SD‡), mm	25.2 (1.9)	28.2 (2.2)	< 0.001§	26.1 (1.7)	27.6 (1.6)	< 0.001§

TG and CG were homogeneous for all the skeletal parameters at baseline, or T0 (P > 0.05; T-test for independent data and Two-sample Wilcoxon rank-sum test). Both groups showed a significant increase in all skeletal parameters in the interval of time from T0 to T1 (P < 0.05; T-test for dependent data and One-sample signed-rank test).
**Iqr is interquartile range.*
† Wilcoxon signed-rank test.
‡ SD is Standard Deviation
§ T-test for dependent data.

TABLE 2 Descriptive statistic (mean and SD; median and interquartile range) of the skeletal parameters of groups TG a CG measured at T0 and T1 and level of statistical significance of their change.

skeletal parameters, representing maxillary and nasal bone ($p > 0.05$; t-test for independent data and Two-sample Wilcoxon rank-sum test).

Regarding the change over the time in the maxillary and nasal structures (T0-T1), the variables displayed a significant increase in the group TG as well as in the group CG ($p < 0.05$; t-test for dependent data and Wilcoxon signed-rank test). The row data of those variables and statistical output of the comparison within each group has been presented in table 2.

Focusing on the amount of difference measured in the nasal bone between the two time points T0 and T1, the variation was homogeneous among all individuals of both groups, and consequently, the modification was considered equivalent (Tab 3). In fact, the statistical tests performed on this change did not give a significant output in the comparison between group TG and CG . All the variables showed an increment except for NBi, which decreased by 2°.

On the contrary, when considering the variables measuring the difference in the maxilla, the increment from T0 to T1 was significantly different between the two groups (Tab 3). In fact, NLd, IOFd and PFd became greater in TG than the corresponding distances in CG ($p < 0.001$; t-test for independent data and Two-sample Wilcoxon rank-sum test).

	Treatment Group (N=26)	Control Group (N=10)	comparison between groups
	Change T0-T1	Change T0-T1	P-value
Upper Nasal Bone Width, UNBw			
median (Iqr*), mm	0.7 (0.6)	1.0 (0.9)	0.9589†
Lower Nasal Bone Width, LNBw			
mean (SD‡), mm	1.2 (0.6)	1.0 (0.5)	0.5941§
Nasal Bone Inclination, NBi			
median (Iqr*), degrees	-2.0 (0.5)	-2.0 (0.8)	0.1978†
Naso Lacrimal Duct distance, NLDd			
mean (SD‡), mm	1.8 (0.5)	1.1 (0.4)	< 0.001§
Infra-Orbital Foramen distance, IOFd			
median (Iqr*), mm	4.1 (1.6)	1.8 (2.0)	< 0.001†
Palatal Foramen distance, PFd			
mean (SD‡), mm	3.0 (0.7)	1.5 (0.6)	< 0.001§

TG presented a clinically relevant difference in the increase limited to NLDd, IOFd, and PFd with respect those of CG ($P < 0.05$; T-test for independent data and Two-sample Wilcoxon rank-sum test).
** Iqr is interquartile range.*
† Two-sample Wilcoxon rank-sum test.
‡ SD is Standard Deviation.
§T-test for independent data.

TABLE 3 Descriptive statistic of the change from T0 to T1 (mean and SD; median and interquartile range) of the skeletal parameters in TG and CG and comparison between the two groups.

Discussion

Very little was found in the literature on the question regarding the enlargement of the nasal bones in children who had received a treatment with a rapid maxillary expander [da Silva Filho et al., 2011]. Therefore, the present study was designed to determine specifically the skeletal effect onto the nasal bones in a group of children, who underwent to a rapid maxillary expansion to correct a posterior cross-bite or to correct anterior crowding.

The most important result of this study was that the transversal expansion was limited to the hard palate and did not affect the nasal bones. In fact, the changes measured at that level corresponded to those recorded in the untreated subjects.

This finding is consistent with the conclusion of the study of da Silva Filho et al. [2011]. However, they applied a different method, and did not measured directly the skeletal change. In fact, the authors evaluated the impact on nasal morphology of the rapid maxillary expansion using facial analysis. Three experienced orthodontists analysed the facial photographs of 60 children treated with a Haas-expander for a posterior cross-bite. Seven percent of children only showed a visible change at one-year follow-up assessment. Consequently, the authors excluded some impact of rapid maxillary expansion treatment on nasal morphology.

In relation to the nasal bones growth and our results, the changes were similar among treated and untreated subjects. The highest change was in the nasal bone inclination with a 2-degree reduction in both groups. Therefore, the expansion treatment seems not to be associated with this change, but with the natural growth and the development of the nose. In fact, in a group of children between 9 and 11 years of age, Burke and Hughes-Lawson found that the change took place mainly in anteroposterior prominence of nasal tip in both sexes and the modification of intercanthal width was not so relevant [Burke and Hughes-Lawson, 1989]. Also, Ferrario et al highlighted that the size of the nose increased until adulthood [Ferrario et al., 1997]. However, this increment occurred more in the vertical and antero-posterior dimensions than in the horizontal dimension from right to left nasal alae. Buschang et al as well discovered that the changes in nasal dorsum are predominately an angulation change first and foremost in the lower dorsum and more evident during adolescence [Buschang et al., 1993].

With regard to the effect of rapid maxillary expansion onto nasal sutures, it seems that in our sample the effect is not relevant. The nasal bone increased after expansion by 0.7 mm and 1.2 mm respectively in upper and lower border, an amount very close to that one of the controls. The skeletal modification was higher than that reported from Ghoneima et al. Those authors evaluated whether the force of a rapid maxillary expander can cause an opening of the cranial and circum-maxillary sutures. Twenty adolescents were monitored with a pre-expansion and post-expansion computed tomography scans. The results confirmed some effect of the procedure onto the sutures. In sequence the width increase obtained was more pronounced in the intermaxillary suture (1.7 mm), then in the internasal suture (0.6 mm), and finally in the maxilla-nasal suture (0.4 mm). The trend of skeletal effects due to rapid maxillary expansion is similar, but data from Ghoneima's study are not comparable with ours because different methods were used. In our study was measured, the increase of the nasal bones width, while in Ghoneima's study was measured the quantitative changes of cranial and the circummaxillary sutures, which is a very small space. Moreover, the authors did not quantify the real size effect of the treatment, since an untreated homogeneous control group was not collected and compared. In addition, it must be highlighted that, the sample of this study comprised adolescents monitored at an age older than that of our study. As a consequence, the response in the sutures to the expansion could have been reduced for this reason [Provatidis et al., 2008; Enlow and Hunter, 1966; Melsen, 1975]. Moving to the maxilla,

some information about the natural expansion of the great palatine foramen - as well as intafraorbital foramen - distances is reported in the paper of Seubert et al. The authors described a transversal increase similar to those obtained in our control group for the infraorbital foramina distance. In fact, the treatment protocol of their research did not include the rapid expansion of the maxilla since the patients did not suffer from a maxillary transverse deficiency. The data were acquired measuring the CBCT scans taken before and after a full orthodontic treatment in 100 children and adolescents. During the observation time the mean change was 1.7 mm for infraorbital foramen distance, and 1.0 mm for great palatal foramen distance. This last value was to some extent lower than the 1.5 mm variation measured in our control group.

Similarly, a lesser amount of change of both distances was reported from Darsey et al., when compared with our data. Unlike the study carried out by Seubert et al, in this investigation the patients were treated with a rapid maxillary expander and monitored with a CBCT. They reported an increase of the greater palatine foramen distance of 1.20 mm and that one between infraorbital foramina of 1.26 mm versus an increment of 3.0 mm and 4.1mm of our TG in the same distances. In Darsey et al. [2012] study the ERP was anchored to permanent teeth, limiting transverse expansion. Furthermore, the overall number of activations performed is not reported by Dersey et al, so the smaller increase in the distance between the palatine foramina and the infra-orbital foramina obtained by them compared to our patients may be due to the lower number of activations performed. As well as in the study of Seubert et al, the authors analysed a sample older than our subjects, condition which could have determined a reduced suture response and consequently the dissimilarity in magnitude among the studies.

This article is the first to investigate the effects of RME in early mixed dentition on nasal bones rather than nasal cavities. The difference between nasal cavities and nasal bones is crucial to understanding the relevance of this scientific contribution to clinical practice. The volume of the nasal cavity can increase even if the nasal bones remain unaffected. Consistent with previous studies that have focused on the relationship between transverse palatal expansion and nasal volume increase [Caprioglio et al.], our results show significant transverse expansion at the level of the palatine foramina. However, the aim of this article is not to confirm that it is possible to increase the volume of the nasal cavities using RPE, but to investigate the changes in the nasal bones. In fact, this article focuses on a new issue: to test whether RME in the early mixed dentition can cause unwanted side effects. That is, changes in the shape and position of the nasal bones and, therefore, any potential esthetic damage to the patient.

The limitations of this study are the need to use a CBCT in order to perform the measurements, and the need to have undergone training in using a software for manipulating 3D images. Anyway CBCT allowed to accurately visualise the maxillo-facial area without the superimposition of other anatomical structures, furthermore the FOV was limited to the region to be investigated.

The measurements were performed on 2D Multi-Planar (MPR) reconstructions, because it's more accurate to locate landmarks in the stack slices than 3D Volume Rendering images [Provatidis et al., 2008; Enlow and Hunter, 1966; Melsen, 1975]. The rendered image depends on many factors including threshold filter applied, which can not standardised and it is user dependent. Otherwise 3D Volume rendering can be useful for qualitative evaluation and to have an overview. The landmarks to measure the LNBw were identified by means the maximum intensity projection (MIP), which facilitates the operator in simultaneously viewing and then detecting the anatomical structures of interest from different viewpoints. MIP is a rendering method validated for anatomical structures visualisation from 3D data [Ho et al., 2020; Fernandes et al., 2014; Sato et al., 1998; Prokop et al., 1997] and primarily used in reconstructions of the representation of skeletal structures.

The reason to use MIP only for LNBw, was to more accurately distinguish the border between the lower nasal bone and maxillary bone, however the measurements were performed on the 2D (MPR).

Nonetheless, another important limitation needs to be noted regarding the present study. The two groups were not homogeneous for ratio boys to girls. In fact, it was close to 1 to 1 in TG versus 2 to 1 in CG. Therefore, the number of female and male subjects was not balanced and this could be considered a confounder, since skeletal growth spurt can be different. Consequently, the increase among girls of the TG cloud be more due to the growth than to the treatment. On the other side, since girls complete puberty earlier than boys, this may affect resistance to the forces of expansion and the effect onto the suture can be reduced. Moreover, the number of girls in the CG is only three, a sample size which does not allow to perform a subgroup analysis to statistically test the difference over sex.

The key strengths of this study are the analysis performed onto CBCT scans and the availability of a non-treated control group. In addition, the patients were monitored at a younger age with a longer follow-up than those reported in previous study with a similar purpose [da Silva Filho et al., 2011]. Then, only one rapid maxillary expander with a specific design was administered from one single clinician, who followed a strict protocol in unique clinical setting. Finally, the subjects were identified with a code masked to the operator, who measured the images, to reduce the risk of a measurement bias.

Conclusions

1. The transversal modification induced with a rapid maxillary expansion was limited to the maxillary bone without involving the nose when the RME was performed in early mixed dentition.
2. The changes recorded in the nasal area seem to be connected to the natural growth of the skeletal structures.
3. Future studies on the current topic are recommended, to develop a full picture of the comprehensive effect of the rapid maxillary expansion treatment onto nasal bone. Therefore, a different design should be adopted, ideally a prospective clinical trial, based onto a homogeneous sample monitored for a longer time, at least until the end of the skeletal growth. Moreover, a visual analysis of the esthetic changes over the time is recommended, assessing the perception of trained orthodontists and laypeople.
4. In this study group of patients, RME in the early mixed dentition did not cause significant changes onto the nasal bones with potential aesthetic consequence. This result may be important for the scientific community and influence the routine of clinical treatments.

References

› Burke PH, Hughes-Lawson CA. Stereophotogrammetric study of growth and development of the nose. Am J Orthod Dentofac Orthop. 1989;96(2):144-51.

› Buschang PH, De La Cruz R, Viazis AD, Demirjian A. Longitudinal shape changes of the

nasal dorsum. Am J Orthod Dentofacial Orthop. 1993;104(6):539-43.
› Cameron CG, Franchi L, Baccetti T, McNamara JA. Long-term effects of rapid maxillary expansion: A posteroanterior cephalometric evaluation. Am J Orthod Dentofac Orthop. 2002;121(2):129-35.
› Caprioglio A, Meneghel M, Fastuca R, Zecca PA, Nucera R, Nosetti L. Rapid maxillary expansion in growing patients: correspondence between 3-dimensional airway changes and polysomnography. Int J Paediatr Otorhinolaryngol. 2014 Jan;78(1):23-7.
› Cozzani P, Rosa M, Cozzani M. Spontaneous permanent molar expansion in crossbite and non-crossbite patients. Eur J Orthod. 1999;21:434.
› Cross DL, McDonald JP. Effect of rapid maxillary expansion on skeletal, dental, and nasal structures: A postero-anterior cephalometric study. Eur J Orthod. 2000;22(5):519-28.
› da Silva Filho OG, do Prado Montes LA, Torelly LF. Rapid maxillary expansion in the deciduous and mixed dentition evaluated through postero-anterior cephalometric analysis. Am J Orthod Dentofac Orthop. 1995;107(3):268-75.
› da Silva Filho OG, Lara TS, Ayub PV, Ohashi ASC, Bertoz FA. Photographic assessment of nasal morphology following rapid maxillary expansion in children. J Appl Oral Sci. 2011;9(5):535-43.
› Darsey DM, English JD, Kau CH, Ellis RK, Akyalcin S. Does hyrax expansion therapy affect maxillary sinus volume? A cone-beam computed tomography report. Imaging Sci Dent. 2012;42(2):83-8.
› Enlow DH, Hunter WS. A differential analysis of sutural and remodeling growth in the human face. Am J Orthod. 1966;52(11):823-30.
› Fernandes TMF, AdamczykJ, Poleti ML, Henriques JFC, Frieland B, Garib DG. Comparison between 3D volumetric rendering and multiplanar slices on the reliability of linear measurements on CBCT images: an in vitro study. J Appl Oral Sci. 2014;23(1):56-63.
› Ferrario VF, Sforza C, Poggio CE, Schmitz JH. Three-Dimensional Study of Growth and Development of the Nose. Cleft Palate-Craniofacial J. 1997;34(4):309-17.
› Garrocho-Rangel A, Rosales-Berber MÁ, Ballesteros-Torres A, Hernández-Rubio Z, Flores-Velázquez J, Yáñez-González E, et al. Rapid maxillary expansion and its consequences on the nasal and oropharyngeal anatomy and breathing function of children and adolescents: An umbrella review. Int J Paediatr Otorhinolaryngol. 2023;171:111633.
› Ghoneima A, Abdel-Fattah E, Hartsfield J, El-Bedwehi A, Kamel A, Kula K. Effects of rapid maxillary expansion on the cranial and circummaxillary sutures. Am J Orthod Dentofac Orthop. 2011;140(4):510-9.
› Gribel BF, Gribel MN, Frazão DC, McNamara JA, Manzi FR. Accuracy and reliability of craniometric measurements on lateral cephalometry and 3D measurements on CBCT scans. Angle Orthod. 2011;81(1):26-35.
› Ho JL, Konda A, Rahman J, Harris E, Korn R, Sabir A, et al. Comparative analysis of three-dimensional volume rendering and maximum intensity projection for preoperative planning in liver cancer. Eur J Radiol Open. 2020;7:100259.
› Lione R, Franchi L, Fanucci E, Laganá G, Cozza P. Three-dimensional densitometric analysis of maxillary sutural changes induced by rapid maxillary expansion. Dentomaxillofacial Radiol. 2013;42(2):71798010.
› Longlax TMC, Monroy G, Boada CNJ, Lugo LAM. Effectiveness of the Maxillary Expansion in the Correction of Crowding and Mixed Dentition. Systematic Review. Int J Odontostomat. 2020;14(1):101-8.
› Mazziotti S, Blandino A, Gaeta M, Bottari A, Sofia C, D'Angelo T, et al. Postprocessing in Maxillofacial Multidetector Computed Tomography. Vol. 66, Canadian Association of Radiologists Journal. Canadian Medical Association. 2015;66(3):212-22.
› Melsen B. Palatal growth studied on human autopsy material. Am J Orthod. 1975;68(1):42-54.
› Mutinelli S, Cozzani M. Rapid maxillary expansion in early mixed dentition: Effectiveness of increasing arch dimension with anchorage on deciduous teeth. Eur J Paediatr Dent. 2015;16(2):115-22.
› Niu X, Di Carlo G, Cornelis MA, Cattaneo PM. Three-dimensional analyses of short- and long-term effects of rapid maxillary expansion on nasal cavity and upper airway: A systematic review and meta-analysis. Orthod Craniofac Res. 2020;23(3):250-76.
› Palaisa J, Ngan P, Martin C, Razmus T. Use of conventional tomography to evaluate changes in the nasal cavity with rapid palatal expansion. Am J Orthod Dentofac Orthop. 2007;132(4):458-66.
› Prokop M, Shin HO, Schanz A, Schaefer-Prokop CM. Use of maximum intensity projections in CT angiography: a basic review. RadioGraphics. 1997;17(2):433-51.
› Provatidis CG, Georgiopoulos B, Kotinas A, McDonald JP. Evaluation of craniofacial effects during rapid maxillary expansion through combined in vivo/in vitro and finite element studies. Eur J Orthod. 2008;30(5):437-48.
› Rosa M, Lucchi P, Manti G, Caprioglio A. Rapid Palatal Expansion in the absence of posterior cross-bite to intercept maxillary incisor crowding in the mixed dentition: A CBCT evaluation of spontaneous changes of untouched permanent molars. Eur J Paediatr Dent. 2016;17(4):286-294.
› Rosa M, Lucchi P, Mariani L, Caprioglio A. Spontaneous correction of anterior crossbite by RPE anchored on deciduous teeth in the early mixed dentition. Eur J Paediatr Dent. 2012;13(3):176-80.
› Rosa M. Cross-bite Correction in Mixed Dentition: Rationale and Clinical Recommendations. Seminars in Orthodontics. 2023;29:177-182.
› Sato Y, Shiraga N, Nakajima S, Tamura S, Kikinis R. Local Maximum Intensity Projection (LMIP. J Comput Assist Tomogr [Internet]. 1998 Nov;22(6):912-7. Available from: http://journals.lww.com/00004728-199811000-00014
› Seubert BJ, Gaalaas L, Larson BE, Grünheid T. Evaluation of transverse maxillary growth on cone-beam computed tomography images. Sci Rep. 2021;11(1):17462.
› Timms DJ, Preston CB, Daly PF. A computed tomographic assessment of maxillary movement induced by rapid expansion. A pilot study. Eur J Orthod. 1982;4(2):123-7.
› Ugolini A, Cerruto C, Di Vece L, Ghislanzoni LH, Sforza C, Doldo T, et al. Dental arch response to Haas-type rapid maxillary expansion anchored to deciduous vs permanent molars: A multicentric randomized controlled trial. Angle Orthod. 2015;85(4):570-6.
› Wertz RA. Skeletal and dental changes accompanying rapid midpalatal suture opening. Am J Orthod. 1970;58(1):41-66.