

F. Cullati\*, A. Mapelli\*\*, G. Beltramini\*,  
M. Codari\*\*, C. L. Pimenta Ferreira\*\*, A. Baj\*,  
A. B. Gianni\*, C. Sforza\*\*

Università degli Studi di Milano, Milan, Italy

\*Department of Odontostomatology and Maxillo-Facial  
Surgery, "Fondazione I.R.C.C.S. Ca' Granda Ospedale Maggiore  
Policlinico", Milan

\*\*Department of Biomedical Sciences for Health, Functional  
Anatomy Research Center (FARC), Milan

email: chiaraella.sforza@unimi.it

# Surface electromyography before and after orthognathic surgery and condylectomy in active laterognathia: a case report

## ABSTRACT

**Background** Condylar hyperplasia is a rare bone disease characterised by excessive development of mandibular condyle, which can lead to the development of asymmetric facial deformity together with malocclusion, mandibular deviation, TMJ and masticatory musculoskeletal system dysfunction. There is not a treatment protocol universally accepted. In order to determine the correct management, treatment and intervention timing of these patients, morphological examinations should be coupled with functional assessments.

**Case report** In the present case report, morphological (bone scintigraphy; orthopantomography; posteroanterior and lateral cephalograms; 3D facial photographs) and functional (surface electromyography of masseter and temporalis muscles) quantitative data of a 20-year-old male patient affected by unilateral condylar hyperplasia are presented. The patient underwent a surgical treatment with high unilateral condylectomy associated to a maxillary Le Fort I osteotomy; as well as orthodontic treatment before and after surgery. Facial morphology and masticatory muscles activity were

assessed before surgery and followed-up 6, 12 and 24 months after surgery. Twenty-four months after surgery, all electromyographic values were normal, and soft-tissue facial asymmetry was negligible at 3D assessment.

**Conclusion** Surface electromyography joins a set of clinical and morphological diagnostic tests that help the surgeon in planning the operation and managing the post-surgical patient.

**Keywords** Hemimandibular hyperplasia;  
Temporomandibular joint; Orthognathic surgery;  
EMG; Stereophotogrammetry

## Introduction

An excessive hemimandibular growth can lead to functional and aesthetic impairments, such as facial asymmetry, occlusal disturbance and temporomandibular joint (TMJ) dysfunction [Portelli et al., 2015; Villanueva-Alcojol et al., 2011]. Obwegeser and Makek [1986] classified mandibular asymmetry due to overgrowth into three categories. Type 1, hemimandibular elongation, with a horizontal growth vector, is characterised by chin deviation toward the contralateral side and mandibular midline deviated to the unaffected side. Prominent features of type 2, hemimandibular hyperplasia, include a vertical growth vector, with an ipsilateral open bite or compensatory vertical overdevelopment of the maxilla on the involved side with canting of the occlusal plane; most commonly the mandibular midline is straight and the chin is less deviated. The third type is a combination of the other two types. The aetiology and pathogenesis of this condition is still uncertain [Lippold et al., 2007].

The diagnosis of condylar hyperplasia is made by a combination of clinical and radiologic findings [Olate et al., 2013; Portelli et al., 2015]. In order to devise the correct surgical plan and to prevent the risk of continuous growth with relapse of the facial and occlusal deformities, it is essential to distinguish active from inactive forms. A scintigraphy is conclusive when the difference in activity between the condyles is higher than 10% [Kaban et al., 1982]. A 6-months to 1-year patient evaluation period was sometimes required before surgery in cases in which condylar activity was uncertain [Janakiraman et al., 2015].

Treatment is primarily surgical, with or without orthodontics and functional rehabilitation, and depends on the status of condylar growth, the degree of severity and the age of the patient [Portelli et al., 2015]. Different surgical options have been proposed to obtain proper occlusion, good aesthetic appearance and to prevent recurrence, ranging from high condylectomy to orthognathic surgery or a combination of both. Surgical

timing is still controversial, with some authors favouring surgery as soon as possible, while others prefer waiting for cessation of excessive bone activity [Marchetti et al., 2000; Wolford, 2003; Wolford et al., 2002].

Diagnosis usually involves clinical and morphological assessments of the craniofacial hard and soft tissues, combined with evaluations of the dental arches and TMJ [Janakiraman et al., 2015; Olate et al., 2013; Portelli et al., 2015]. Few authors investigated the function of the main masticatory muscles before and after condylectomy, and only qualitative evaluations were provided [Arun et al., 2002; Brusati et al., 2010; Lippold et al., 2007; Sugawara et al., 2002; Wolford et al., 2002].

Considering that the surgical and orthodontic treatment of these patients involves three-dimensional modifications of the facial skeleton and relative position of the bones, dental arches and occlusal plane, functional examinations are necessary to better plan the interventions and the subsequent rehabilitation [Janakiraman et al., 2015; Ortu et al., 2016; Sforza et al., 2008].

In the current case report, together with conventional morphological assessments, the activity of the masseter and anterior temporalis muscles of a young male patient affected by unilateral condylar hyperplasia were examined by using surface electromyography (EMG) during the performance of standardised static and dynamic tasks. Muscular function was assessed before surgery and followed up 6, 12 and 24 months after surgery.

## Materials and methods

### Diagnosis and clinical procedures

We report a case of a young man aged 20 years diagnosed with mandibular asymmetry due to a left hemimandibular hyperplasia (Fig. 1). A 99MTc04-MDB (methylene diphosphonate) bone scintigraphy detected a pattern of radioisotope uptake characteristic of active laterognathia (Fig. 2). The patient had a complete clinical examination including measurement of the maximum interincisal opening and lateral excursions to the right and left side, evaluation of the jaw models, orthopantomography, and posteroanterior and lateral cephalograms (Fig. 3).

The patient face was imaged with a stereophotogrammetric instrument (Vectra; Canfield Imaging Systems, Fairfield, NJ), and 3D photographs of his face were taken [Janakiraman et al., 2015]. Three-dimensional color maps were generated by the superimposition of his right-side (healthy) half face on his left side (affected) half face, and the asymmetry quantified (Fig. 4). Both the frontal and the three-quarters images showed a marked asymmetry on the lower third of the face, with the mandibular regions being displaced 3–4 mm more on the left than on the

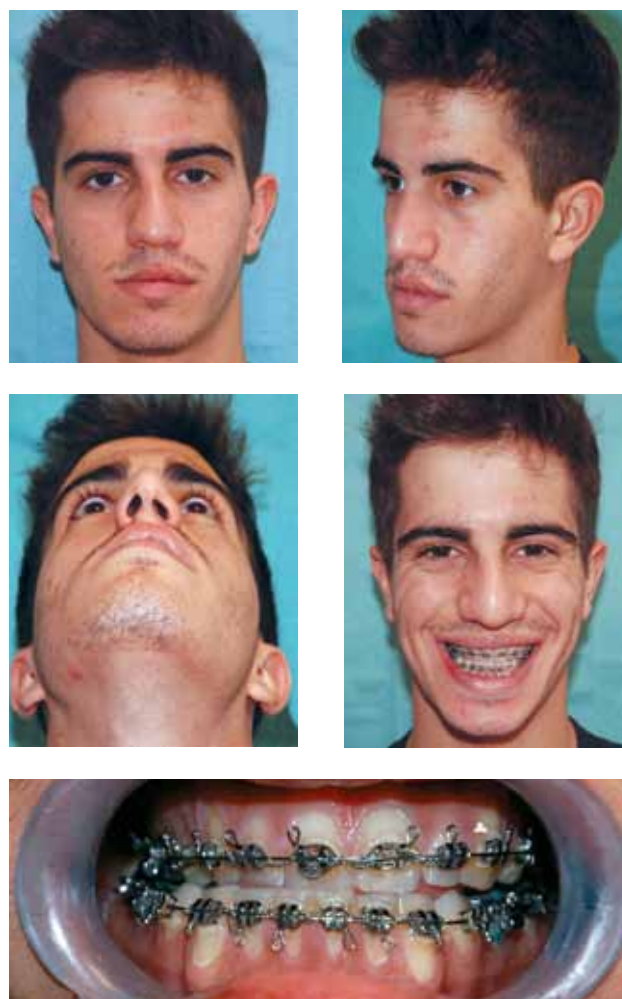


FIG. 1 (A-E) Pre-surgery photographs: mandibular asymmetry due to left hemimandibular hyperplasia with dental Class III malocclusion, concave profile for maxillary deficiency, a modestly prognathic mandible, frontal occlusal plane cant and non-coincident soft tissue skeletal and dental midlines.

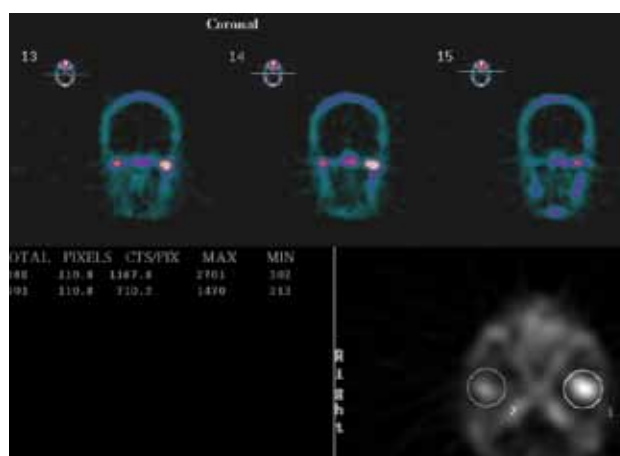


FIG. 2 Pre-surgery 99MTc04-MDB (methylene diphosphonate) bone scintigraphy; the left mandibular condyle shows an increased uptake of radioisotope.

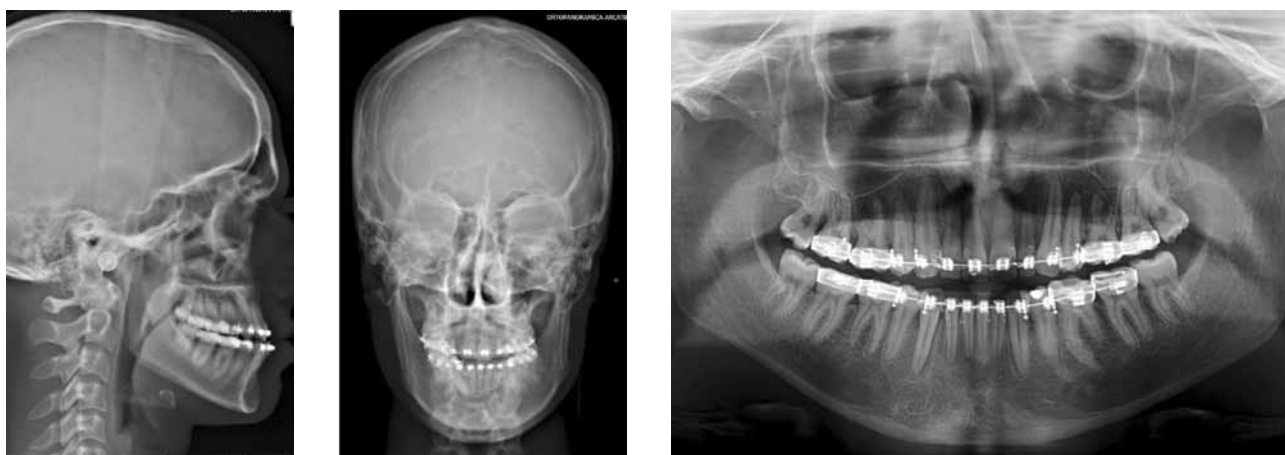

FIG. 3 A Pre-surgery LL cephalometric radiography. B Pre-surgery PA cephalometric radiography. C Pre-surgery panoramic radiography.

right side.

Active condylar growth, age and occlusal plane obliquity due to a compensatory maxillary overdevelopment addressed to high condilectomy and orthognathic surgery after a presurgical orthodontic treatment. Surgical movements were planned during a model operation. Informed consent was obtained for all medical and surgical procedures, as well as for the EMG and 3D imaging study (according to the Ethical Committee Fondazione I.R.C.C.S. Ca' Granda Ospedale Maggiore Policlinico, Milano, 12 July 2011). All procedures were performed according to the ethical standards of the Declaration of Helsinki.

The patient began orthodontic treatment 11 months before surgery; he was operated under general anaesthesia, with naso-tracheal intubation. The first step was a Le Fort I osteotomy to correct the position of the occlusal plane. A high condilectomy was then performed by a preauricular approach [Al-Kayat and Bramley, 1979]. A horizontal osteotomy line was drawn 4–5 mm caudal to the edge of the condylar head on the affected side, and the bone was resected; the surface of the residual condylar head was reshaped. The specimen was sent for histopathological examination. Interocclusal splints were used to guide and maintain planned results. After 7 days of intermaxillary fixation, functional rehabilitation according to Delaire technique [Delaire et al., 1975] was started with active bands and continued for 4 weeks. The orthodontic finishing period started 6 weeks after surgery.

### Surface EMG

Clinical evaluation was performed once weekly for 2 months, then at 6, 12 and 24 months. The patient had also a quantitative analysis of the activity of his masticatory muscles before surgery and 6, 12 and 24 months after surgical treatment. Right and left masseter and anterior temporalis muscles were examined. After

scrubbing the skin with an alcohol soaked gauze pad, disposable Ag/AgCl bipolar pre-gelled electrodes (sensor area, 3.14 cm<sup>2</sup>; inter-electrode distance, 2 cm; Kendall, Covidien, Mansfield, Canada) were positioned along the main direction of the muscular fibers, detected by palpation.

Surface EMG activity was then recorded by means of a wireless EMG system (FreeEMG, BTS S.p.A., Garbagnate Milanese, Italy), with light probes clipped to the electrodes. The analog EMG signal was amplified and digitised (gain 150, resolution 16 bit, sensitivity 1 mV, temporal resolution 1 ms) using a differential amplifier with a high common mode rejection ratio (CMRR>110 dB in the range 0–50 Hz, input impedance>10 GΩ). All the recorded EMG signals were digitally band-pass filtered between 80 and 400 Hz with a 2nd order Butterworth filter, and rectified by calculating the root

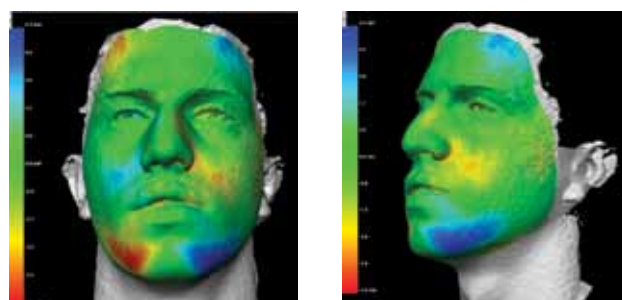


FIG. 4 Three-dimensional colour maps generated by the superimposition of the patient's right-side (healthy) half face on his left side (affected by condylar hyperplasia) half face. Pre-surgery 3D frontal and three-quarters photographs showing a marked asymmetry on the lower third of the face. Beside every image a colour scale graph quantifies the degree of asymmetry between the two half face. Green indicates symmetric regions; red and blue indicate regions that are more asymmetric than 3 mm.

mean square (RMS) in temporal windows of 25 ms.

The subject, sitting on a chair with his head in a natural erect position, was asked to perform two experimental tasks: a 5 s maximum voluntary clench (MVC) and two 15 s unilateral (right and left) gum chewing tests. To standardise the EMG signals of the four analysed muscles, two 10 mm-thick cotton rolls were positioned on his mandibular second premolar/first molars, and a further 5 s MVC (COT) was recorded [Tartaglia et al., 2008]. The 3 s interval with the most stable signals was automatically selected and the corresponding mean value of each muscle's RMS sequence was referred to as 100% of amplitude. To avoid any fatigue effect, a rest period of 3 min was allowed between standardisation and functional recordings.

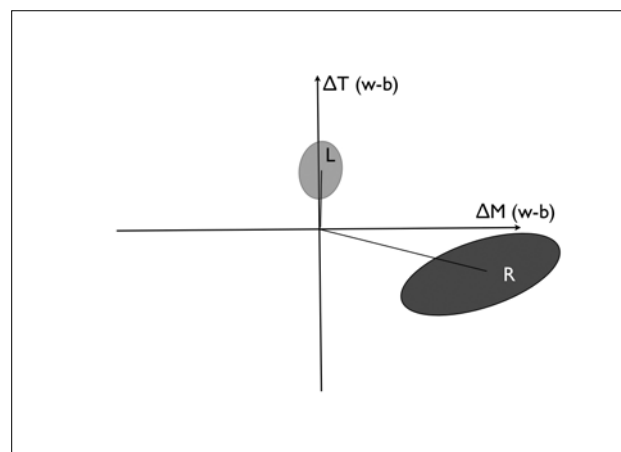
- Maximum voluntary clench

The subject was invited to clench his teeth in intercuspal position as hard as he could, and to maintain the same level of contraction for 5 s. The 3 s period with the most constant EMG signals was automatically detected, its four RMS samples standardised, and used for the computation of the percentage overlapping coefficient (POC) indices [Ferrario et al., 2006]. These coefficients quantify the temporal coordination of the standardised activities, ranging between 0% (no equilibrium) and 100% (perfect coordination). Temporalis (POCT) and masseter (POCM) muscles indices assessed the degree of right-left symmetry; the torsion coefficient (POCTORS) quantified the potential force momentum [Ferrario et al., 2006]. Another index assessed the degree of cooperation between bilateral temporalis and masseter muscles' activities (POCTM).

- Mastication: Unilateral gum chewing

The subjects performed 15 s unilateral chewing of a pre-softened sugarless gum (1.5 g; Mentadent Integral, Unilever Italia, Milan, Italy) on both sides of his mouth. The EMG signals of the four muscles were standardised on COT reference values as detailed for MVC, the masticatory cycles were automatically detected and the chewing frequency computed [Tartaglia et al., 2008].

A bivariate analysis was performed on the simultaneous differential right-left masseter (rM-IM, x-axis) and temporalis (rT-IT, y-axis) standardised activity (Lissajous's Cartesian plot) [Kumai, 1993; Tartaglia et al., 2008]. The 90%-standard ellipse area was computed to estimate the variability in the pattern of contraction of masticatory muscles: wide ellipses correspond to lowly repeatable muscular patterns, while narrow ellipses indicate a reduced variability for the same task [Tartaglia et al., 2008]. To directly compare right- and left-side chewing ellipses, the latter was mirrored, making the  $\Delta M$  and  $\Delta T$  coordinates represent the differentials between the working side muscles and the balancing side ones; positive values of the two thus indicated a prevalence of the working side muscular activities. Then, the pair



**FIG. 5** Lissajous plot of differential working-balancing (w-b) masseter ( $\Delta M$ ) and temporalis ( $\Delta T$ ) muscles activities. R, right side chewing; L, left side chewing. Patient's before-surgery condition is reported.

of coordinates of each ellipse's center,  $\Delta M_{\text{center}}$  and  $\Delta T_{\text{center}}$ , were calculated, as well as the symmetrical mastication index (SMI) [Tartaglia et al., 2008], to assess if the two unilateral chewing tasks were performed with symmetrical muscular patterns (Fig. 5). The total standardised activity of the four muscles during the 15 s chewing test was computed as the sum of the four integrated areas of the EMG signals over time (Global activity). Also, the percentage of the activity referred to the working side muscles (wActivity) was calculated.

For all chewing indices other than SMI, the mean between right and left chewing side values was calculated, and the inter-side differences were quantified by indices of symmetry (SIs), calculated as the ratio between the lower side value and the higher of the two. For all SI variables, 100% indicated the best symmetry condition.

### Statistical analysis

For each follow-up stage, all patient's EMG parameters were compared to the corresponding sample distributions of a control group of normal subjects of similar age (seven men, 10 women; mean age, 20.6 years; SD, 1.1). EMG examination of these subjects was made with the same procedures detailed above. The tolerance interval covering at least a proportion of 95% of the control population (TI95%) was computed for each standardised parameter. One-sided or two-sided 95%-tolerance intervals were arbitrarily chosen depending on the characteristics of the indices as follows

- one-sided TI95% with lower limit for: POC indices, SMI,  $\Delta M_{\text{center}}$ ,  $\Delta T_{\text{center}}$ , wActivity and the SI indices;
- two-sided TI95% with symmetric bilateral limits for: Chewing frequency, 90%-standard ellipse area, Global activity.

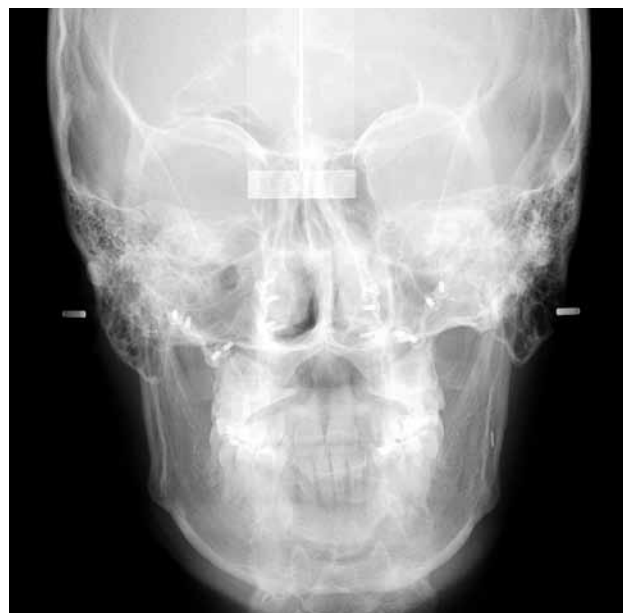
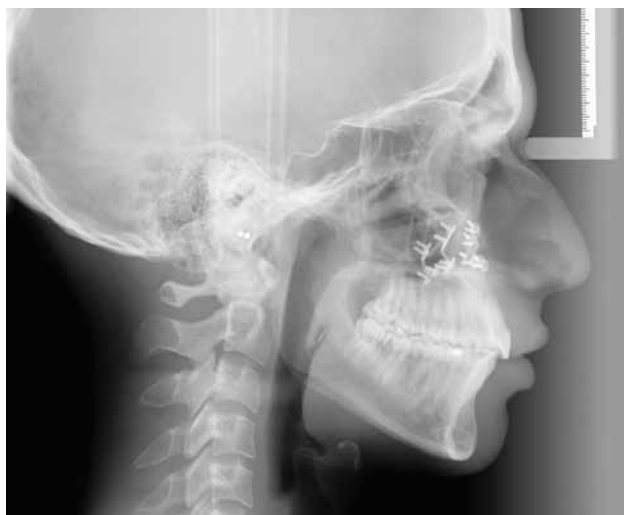
FIG. 6 LL cephalometric radiograph (a) and PA cephalometric radiography (b) 6 months post-surgery.

## Results

Histopathological examination of the condylar head revealed thickened irregular bony trabeculae, uninterrupted layer of undifferentiated mesenchymal cells, hypertrophic cartilage, islands of chondrocytes in subchondral trabecular bone and increased thickness of the cartilaginous layer. These patterns confirmed the clinical diagnosis of condylar hyperplasia.

Clinical findings such as midline deviation, chin asymmetry, contralateral crossbite, maxillary cant, TMJ function were collected pre-operatively, and reevaluated at the 2, 6, 12 and 24 months follow-up visits. No short and long-term morbidity was observed. No TMJ disturbances were detected.

At the 6, 12 and above all at the 24 months follow-up, the clinical examination showed an improved facial balance without recurrence of asymmetry, stable Angle Class I occlusion (Fig. 6), normal maximum interincisal opening, with only a slight left mandibular deviation in maximum mouth opening 6 months after surgery; lateral and anterior excursions were correctly preserved (Fig. 7). Regarding the muscular component, the patient showed no altered muscular behaviour during the static MVC task, either before or at any stage after surgery; differently, some anomalous EMG parameters were observed during gum chewing (Table I). In particular, before surgery, he had a remarkable asymmetry between the right and left chewing side muscular pattern variability (90% std. ellipse area: right side, 3573%<sup>2</sup>; left side, 694%<sup>2</sup>) that disappeared after surgery. Also the pre-surgery global muscular activity was asymmetric, when right and left unilateral chewing were compared (global activity: right side, 854%•s; left side, 390%•s), remaining anomalous also 12 months after surgery (right side, 500%•s; left side, 283%•s). Six month after

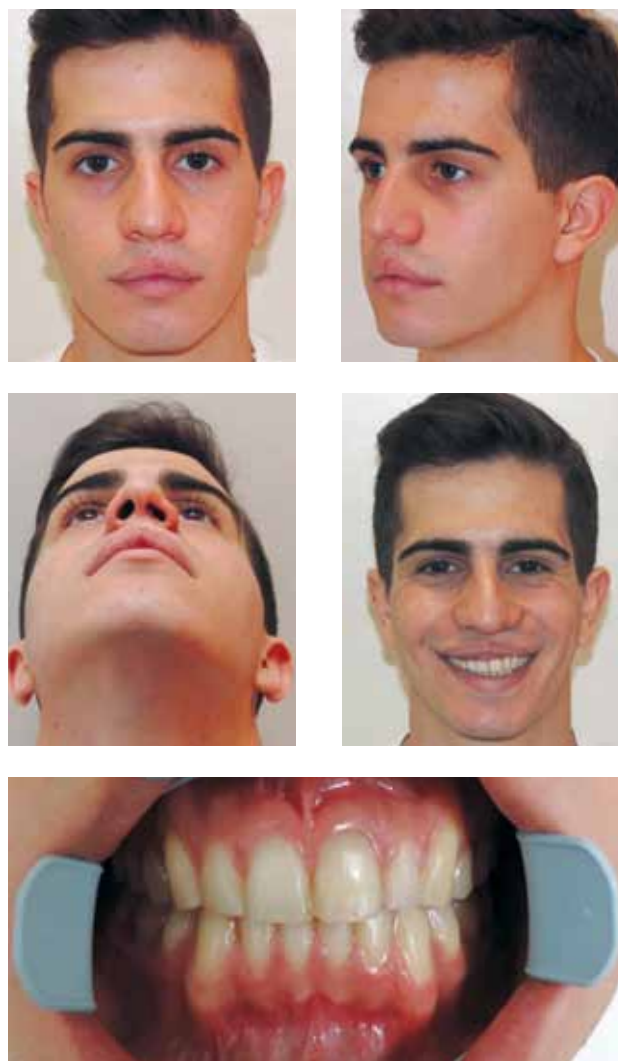


FIG. 7 Post-surgery photographs after 12 months: good esthetic and occlusal outcomes.

		Controls	Before surgery	6 mo. follow up	12 mo. follow up	24 mo. follow up
MVC	unit					
POC <sub>T</sub>	%	87.0 (2.8)	88.6	87.3	87.5	89.5
POC <sub>M</sub>	%	86.6 (3.2)	87.4	85.9	88.0	90.1
POC <sub>TORS</sub>	%	90.6 (1.9)	92.4	93.1	91.8	93.1
POC <sub>TM</sub>	%	89.8 (2.9)	93.1	93.2	90.8	91.9
Chewing	unit					
Frequency	Hz	1.33 (0.25)	1.51	1.32	1.37	1.45
ΔM_center	%	52 (33)	47	61	33	30
ΔM_center-SI	%	62 (42)	2	71	82	16
ΔT_center	%	38 (26)	12	-26 *	8	7
ΔT_center-SI	%	35 (56)	-41	-23	-38	-42
Std. ellipse area	% <sup>2</sup>	9898 (5918)	2134	18499	1580	2891
Std. ellipse area-SI	%	61 (23)	19 *	42	41	96
Global activity	%*s	672 (294)	622	1072	392	549
Global activity-SI	%	84 (12)	46 *	74	57 *	73
wActivity	%	64 (8)	66	58	62	60
wActivity-SI	%	91 (9)	91	98	95	94
SMI	%	62 (30)	20	44	53	29

Control values are expressed as: mean (SD).  
 \* = patient's anomalous value, not included in the relevant 95%-tolerance interval of the control group.  
 MVC, maximum voluntary clench; COT, MVC with cotton rolls; POC, percentage overlapping coefficient; M, masseter muscle; T, temporalis muscle; TORS, torsion; TM, co-operation between temporalis and masseter muscles; SI, symmetry index; SMI, symmetrical mastication index.

TABLE 1 Electromyographic parameters of Maximum Voluntary Clench (MVC) and unilateral gum chewing.

surgery, the patient had an altered activity distribution between working side and non-working side muscles during unilateral right side chewing ( T\_center, -67%), with the left temporalis muscle prevailing over the right one. This abnormality disappeared in the following months. After 24 months, all functional indices were in line with those of the control subjects.

The good functional result was coupled with a symmetric 3D facial image (Fig. 8).

### Discussion

Condylar hyperplasia is a pathological condition that presents a challenge because of its progressiveness and the severe dentofacial deformity it can produce [Portelli et al., 2015]. Condylar growth activity and pattern, severity of asymmetry and the age of the patient influence surgical timing and the types of corrective surgical procedures. High condylectomy involves removing the top 4-5 mm of condylar head, the hyperactive growth site responsible for dysmorphism [Lippold et al., 2007]. This allows a more balanced facial development and prevents postoperative relapse.

Among the objectives of a successful treatment, the achievement of a harmonic appearance of the craniofacial soft and hard tissue structures should be coupled with sound and symmetric muscular and articular activities. To the best of our knowledge,

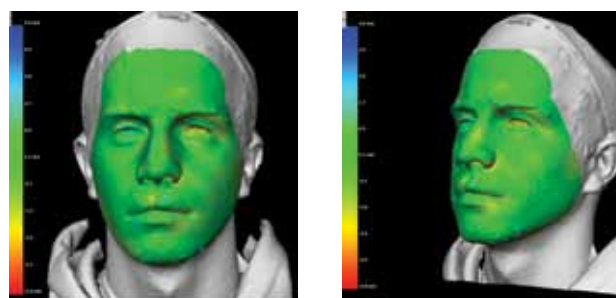


FIG. 8 Three-dimensional colour maps generated by the superimposition of the patient's right-side (healthy) half face on his left side (affected by condylar hyperplasia) half face. 3D photographs taken 24 months after surgery, frontal and three-quarters views, showing a good recovery of global facial symmetry and an excellent stability of the hard and soft tissues. Beside every image a colour scale graph quantifies the degree of asymmetry between the two half face. Green indicates symmetric regions; red and blue indicate regions that are more asymmetric than 3 mm.

no previous investigation reported quantitative assessments of masticatory muscle function in patients with mandibular hyperplasia, and only qualitative information was provided [Arun et al., 2002; Brusati et al., 2010; Lippold et al., 2007; Sugawara et al., 2002; Wolford et al., 2002].

In the present case report, a series of quantitative surface EMG evaluations including both static and

dynamic tasks were performed both before and after the combined surgical and orthodontic treatment, and data were compared to those collected in healthy subjects. Comparing data collected before surgery with those obtained at the 6, 12 and 24 months follow-up examinations, we can see a general basically positive framework, focused on functional improving. MVC parameters appear to be normal in the pre-surgery acquisition and they remain so alongside all the follow-up phases, finally stabilising at higher values, on average, than those recorded at point 0. Therefore, the combination of surgery and orthodontic treatment did not interfere with the maximum capacity of voluntary clenching of the patient, and a functional, essential feature for a good quality of life remains unaltered.

The dynamic unilateral chewing tests unveiled a more complex situation and showed a number of particularly interesting data. In the pre-surgery assessment, the patient demonstrated a significant asymmetry in the patterns of right and left muscular variability; indeed, when the patient chewed on his left side, affected by condylar hyperplasia, there was a reduced value of global muscular activity with decreased standardised potentials of the individual muscles, a situation compatible with a reduced muscular strength [Tartaglia et al., 2008]. At the same time, the area of the right-side standard ellipse was importantly larger than the left-side area. Besides to the orthodontically-induced incorrect pre-surgical occlusal pattern, these results could be explained by the limited range of mandibular movements, mandibular deviation and right-side crossbite, which could lead the patient to chew unilaterally on the unaffected side, with more vertical, shorter and irregular movements.

The unfavourable skeletal relations in individuals with dentofacial deformities and impaired occlusion lead to alterations in the masticatory function, which usually involve lower values of electromyographic activities, greater asymmetry indices and altered patterns of jaw movements [Ortu et al., 2016; Picinato-Pirola et al., 2012], with more vertical movements and even excessive use of the dorsum of tongue during chewing. Thus, the greater area of the right-side standard ellipse indicates a larger variability in chewing patterns, resulting from the different muscular recruitment strategies in each masticatory cycle/stroke.

Only 6 months after surgery, these data totally changed, becoming fully comparable with the normality range 24 months after surgery. The only value that appears altered after surgery (6 months) probably indicates a variable masticatory pattern, above all during right side chewing, still looking for stability. In fact, during unilateral right side chewing there is a greater activation of the left temporalis muscle, probably with a vicarious function on the left condylar instability caused by the high condylectomy.

Features like these seem to be related to differential

activation strategies, trying to maintain the function and the balance of the stomatognathic system. After surgery, the strategy of motor units recruitment must adapt to the new musculoskeletal condition and different sensory experiences. However, this occurs gradually and, especially in the first six months, patients usually have pain, oedema, limitation of mouth opening [Phillips et al., 2008] and changes in sensitivity [Oth et al., 2013] which can still provide changes in muscular activation and recruitment.

Although there were more harmonious skeletal relationships, occlusal stability has not yet been fully achieved in the postoperative 6-month assessment. Furthermore, the stability of orthognathic surgery is related to surgical technique, type of fixation and muscular and functional aspects of each individual [Trawitzki et al., 2010]. The patient may take some time to adapt, with possible alterations of masticatory function in the first months after surgery, but improving subsequently, when also the occlusion is more stabilised.

Finally, 24 months after surgery, none of the parameters obtained by the EMG analysis was outside the normal reference interval. Therefore, we have an objective, quantitative confirmation that the patient who had had condylar hyperplasia has achieved excellent anatomical and functional results, thanks to the treatment with maxillary Le Fort I osteotomy and high left condylectomy in association with pre-and post-surgical orthodontic treatment. The good morphological symmetry was also quantitatively confirmed by the analysis of the 3D facial photographs [Janakiraman et al., 2015]. Indeed, 3D facial analysis using stereophotogrammetry can well complement conventional symmetry analysis made by orthopantomography [Diéguez Pérez et al., 2016].

Correcting the facial skeleton and the dental occlusion increases the occlusal contacts, favoring the conditions for muscle contraction [Trawitzki et al., 2010]. Also, in the patient analysed in the current case report, the recovery of jaw movements in a period of approximately 24 months may have helped a better chewing function and consequently adequate EMG indices during this function. Possibly, the recovery of a good static muscular activity, as detected during the MVC test, can be obtained very early after the surgical treatment [Arun et al., 2002; Brusati et al., 2010; Sugawara et al., 2002], while the restoration of dynamic muscular patterns, necessary for chewing, may need a longer time. Both activities should be assessed by EMG analysis, thus supplying a more complete picture of the patient's situation [Tartaglia et al., 2008].

## Conclusion

If an evidence of abnormal growth is present, condylar surgery is mandatory before a severe facial deformity develops. It is expected that the removal of the

condyle will arrest the excessive and disproportionate development of the mandible, limiting progressive asymmetry during the active phase of the disease, and providing stable long-term results. High condylectomy appears to be a relevant surgical method to correct unilateral condylar hyperplasia [Ghawsy et al., 2016]; this technique should be considered the elective treatment of active condylar hyperplasia in adults and it is even more advisable in immature patients.

In younger patients, the aims are to prevent progression of the deformities and to restore facial symmetry and occlusion spontaneously, if performed early (10-12 years of age) [Almeida et al., 2015]. The authors advise not to wait the end of growth because compensatory changes in maxilla, dentoalveolar structures and soft tissues can compromise surgical optimal outcomes [Almeida et al., 2015]. In adults, conventional orthognathic surgery alone is not adequate in active condylar hyperplasia.

Condylectomy and simultaneous orthognathic surgery of single or both jaws have predictable and stable results in terms of facial symmetry and unimpaired joint function [Brusati et al., 2010; Lippold et al., 2007; Portelli et al., 2015; Wolford, 2003]. However, further research is necessary to determine a valid standardised method of diagnostic approach to this type of pathology. In this context, surface EMG joins a set of clinical and morphological diagnostic tests (clinical examination, 3D photography, radiography, planar scintigraphy, SPECT, PET) that help the surgeon in planning the operation and in managing the post-surgical patient; this tool gives us functional information of the musculoskeletal district involved in the disease, non-invasively and with low cost.

### Consent

Written informed consent was obtained from the patient's parent for publication of this case report and accompanying images. A copy of the written consent is available for review by the Editor-in-Chief of this journal.

### Competing interests

The authors declare that they have no competing interests.

## References

- › Al-Kayat A, Bramley P. A modified pre-auricular approach to the temporomandibular joint and malar arch. *Br J Oral Surg* 1979;17:91-103.
- › Almeida LE, Zacharias J, Pierce S. Condylar hyperplasia: An updated review of the literature. *Korean J Orthod* 2015;45:333-340.
- › Arun T, Kayhan F, Kiziltan M. Treatment of condylar hypoplasia with distraction osteogenesis: a case report. *Angle Orthod*. 2002;72:371-376.
- › Brusati R, Pedrazzoli M, Colletti G. Functional results after condylectomy in active laterognathia. *J Craniomaxillofac Surg* 2010;38:179-184.
- › Delaire J, Le Roux JC, Tuslane JF. Le traitement fonctionnel des fractures du condyle mandibulaire et de son col. *Rev Stomatol Chir Maxillofac* 1975;76:331-350.
- › Diéguez Pérez M, De Nova García J, Mourelle Martínez MR, Feijoo García G. Indicators of jawbone asymmetry through analysis of panoramic radiographs *Eur J Paediatr Dent* 2016;17:136-140.
- › Ferrario VF, Tartaglia GM, Galletta A, Grassi GP, Sforza C. The influence of occlusion on jaw and neck muscle activity: a surface EMG study in healthy young adults. *J Oral Rehabil* 2006;33:341-348.
- › Ghawsy S, Aagaard E, Thygesen TH. High condylectomy for the treatment of mandibular condylar hyperplasia: a systematic review of the literature. *Int J Oral Maxillofac Surg* 2016;45: 60-71.
- › Janakiraman N, Feinberg M, Vishwanath M, Nalaka Jayaratne YS, Steinbacher DM, Nanda R, et al. Integration of 3-dimensional surgical and orthodontic technologies with orthognathic "surgery-first" approach in the management of unilateral condylar hyperplasia. *Am J Orthod Dentofacial Orthop* 2015;148:1054-1066.
- › Kaban LB, Cisneros GJ, Heyman S, Treves S. Assessment of mandibular growth by skeletal scintigraphy. *J Oral Maxillofac Surg*. 1982;40:18-22.
- › Kumai T. Difference in chewing patterns between involved and opposite sides in patients with temporomandibular joint and myofascial pain-dysfunction. *Arch Oral Biol* 1993;38:467-478.
- › Lippold C, Kruse-Losler B, Danesh G, Joos U, Meyer U. Treatment of hemimandibular hyperplasia: the biological basis of condylectomy. *Br J Oral Maxillofac Surg* 2007;43:351-360.
- › Marchetti C, Cocchi R, Gentile L, Bianchi A. Hemimandibular hyperplasia: treatment strategies. *J Craniofac Surg* 2000;11:46-53.
- › Obwegeser HL, Makek MS. Hemimandibular hyperplasia – hemimandibular elongation. *J Maxillofac Surg* 1986;14:183-208.
- › Olate S, Netto HD, Rodriguez-Chessa J, Alister JP, de Albergaria-Barbosa J, de Moraes M: Mandible condylar hyperplasia: a review of diagnosis and treatment protocol. *Int J Clin Exp Med* 2013; 6:727-737.
- › Ortu E, Lacarbonara M, Cattaneo R, Marzo G, Gatto R, Monaco A. Electromyographic evaluation of a patient treated with extraoral traction: a case report. *Eur J Paediatr Dent* 2016;17:123-128
- › Oth O, Louryan S, Van Sint Jan S, Rooze M, Glineur R. Impact of the mandibular divergence on the position of the inferior alveolar nerve and mylohyoid nerve: a computed tomography study and its relevance to bilateral sagittal split osteotomy. *Surg Radiol Anat* 2013;35:241-247.
- › Phillips C, Blakey G 3rd, Jaskolka M. Recovery after orthognathic surgery: short-term health-related quality of life outcomes. *J Oral Maxillofac Surg* 2008;66:2110-2115.
- › Picinato-Pirola MN, Mestriner W Jr, Freitas O, Mello-Filho FV, Trawitzki LV. Masticatory efficiency in class II and class III dentofacial deformities. *Int J Oral Maxillofac Surg* 2012;41:830-834.
- › Portelli M, Gatto E, Matarese G, Miliati A, Catalfamo L, Gherlone E, Lucchese A. Unilateral condylar hyperplasia: diagnosis, clinical aspects and operative treatment. A case report. *Eur J Paediatr Dent* 2015;16:99-102.
- › Sforza C, Peretta R, Grandi G, Ferronato G, Ferrario VF. Soft tissue facial planes and masticatory muscle function in skeletal Class III patients before and after orthognathic surgery treatment. *J Oral Maxillofac Surg* 2008;66:691-698.
- › Sugawara Y, Hirabayashi S, Susami T, Hiyama S. The treatment of hemimandibular hyperplasia preserving enlarged condylar head. *Cleft Palate Craniofac J* 2002;39:646-654.
- › Tartaglia GM, Testori T, Pallavera A, Marelli B, Sforza C. Electromyographic analysis of masticatory and neck muscles in subjects with natural dentition, teeth-supported and implant-supported prostheses. *Clin Oral Implants Res* 2008;19:1081-1088.
- › Trawitzki LV, Dantas RO, Mello-Filho FV, Marques W Jr. Masticatory muscle function three years after surgical correction of Class III dentofacial deformity. *Int J Oral Maxillofac Surg* 2010;39:853-856.
- › Villanueva-Alcojol L, Monje F, Gonzalez-Garcia R. Hyperplasia of the mandibular condyle: clinical, histopathologic, and treatment considerations in a series of 36 patients. *J Oral Maxillofac Surg* 2011;69:447-455.
- › Wolford LM, Mehra P, Reiche-Fischel O, Morales-Ryan CA, Garcia-Morales P. Efficacy of high condylectomy for management of condylar hyperplasia. *Am J Orthod Dentofacial Orthop* 2002;121:136-150.
- › Wolford LM. Concomitant temporomandibular joint and orthognathic surgery. *J Oral Maxillofac Surg* 2003;61:1198-1204.