

A. Theocharopoulou, M.D. Lagerweij,  
A.J.P. van Strijp

Department of Cariology Endodontology Pedodontology,  
Academic Centre for Dentistry Amsterdam (ACTA), Amsterdam,  
The Netherlands

e-mail: katerina5the@gmail.com

## Use of the ICDAS system and two fluorescence-based intraoral devices for examination of occlusal surfaces

### ABSTRACT

**Aim** The aims of this study were to assess the inter-examiner reliability of ICDAS and Soprolife intra-oral camera ex vivo using 5 examiners and to compare in vivo the validity of two fluorescence-based intra-oral devices in examining occlusal surfaces with early carious lesions.

**Materials and methods** Thirty-seven occlusal surfaces of posterior primary and permanent teeth of 20 children were examined using Diagnodent pen (KaVo, Biberach/RiB, Germany) and Soprolife (Acteon Group, La Ciotat, France) fluorescence intra-oral camera. The white light photos, made by Soprolife camera, were evaluated using ICDAS scores and the Soprolife fluorescence photos were scored as sound, enamel caries and dentine caries by 5 experienced dentists. The dentists were trained for the use of ICDAS system with a short online training programme (ICDAS.org) and for the scoring of caries on the fluorescence images with example images. Statistics: cut-offs were made for ICDAS, Soprolife and Diagnodent to distinguish sound surfaces and enamel caries from dentinal caries. The inter-examiner reliability was calculated using intra-class correlation coefficient.

**Results** On white light images the examiners found 16 enamel caries and 21 dentine caries with the ICDAS system. On the Soprolife fluorescent images 24 enamel lesions, 9 dentine lesions and 4 sound surfaces

were observed. The inter-examiner reliability (ICC) of the ICDAS system on white light photographs and of Soprolife on the fluorescent images for average measures was 0.70 and 0.72, respectively. The sensitivity and specificity of Soprolife (95%CI) was 0.43 and 1.0 respectively, using ICDAS as a reference standard. The sensitivity and specificity of Diagnodent (95%CI) was 0.62 and 0.81 respectively.

**Conclusion** A short training of dentists in the use the ICDAS system resulted in satisfactory inter-examiner reliability for the analysis of occlusal lesions on white light images. Soprolife and Diagnodent do not contribute to a better detection of early carious lesions.

**Keywords** Early carious lesions, fluorescence-based caries detection devices, ICDAS system.

### Introduction

Current commonly used caries detection methods include visual inspection, tactile use of an explorer and radiographs. Visual examination shows a sensitivity of 65.6% and a specificity of 82.4% compared to histology [Boye et al., 2012]. *In vitro* studies have shown that diagnosis by means of the explorer is correct in less than 50% of cases [Lussi, 1991]. Intraoral bitewing radiographs show high sensitivity (0.69-0.84) and specificity (0.94-0.99) in detecting approximal caries lesions [Kamburoglu et al. 2012], but are ineffective in detecting occlusal caries, due to the amount of sound tissue attenuating the beam [Featherstone, 2000]. For detecting hidden occlusal caries, the sensitivity and specificity of visual-tactile examination when compared to digital radiography is 90% and 44% respectively [Chong et al., 2003]. If carious lesions are detected early enough, especially in the occlusal surfaces of primary teeth, intervention methods, such as fluoride application, sealants and preventive resin restorations can be applied to halt the caries process.

Visual inspection can be subjectively based on a clinician's experience and training. Standardised visual inspection systems should be adopted to avoid inconsistencies amongst diagnoses from different dentists as different factors lead to the detection of a lesion. When lesions start to form the enamel crystals dissolved and replaced by water, saliva, plaque fluid. The optical properties of the enamel change and can be detected. This is the foundation of the clinical optical detection method with the naked eye. The International Caries Detection and Assessment System (ICDAS) provides a standardised method of lesion detection and assessment, leading to caries diagnosis. The sensitivity of ICDAS-II varies between 63.1%-100%, using scores

2-3 to differentiate sound sites from those with dentine caries with histology as a gold standard. The specificity of ICDAS-II varies from 69%-93% for detecting occlusal dentinal caries. [Shoab et al., 2009; Diniz et al., 2009; Jablonski-Momeni et al., 2008].

Fluorescence is a property of some manmade and natural materials that absorb energy at certain wavelengths and emit light at longer wavelengths. Several caries detection methods, such as DIAGNOdent (KaVo, Biberach/Riß, Germany) and the Soprolife intraoral camera (Acteon Group, La Ciotat, France), are based on the (auto)fluorescence of teeth.

DIAGNOdent illuminates the tooth surface with red laser light and measures the emitted fluorescence. The changes in the mineral content and porosity of the tooth surface and the presence of porphyrins, produced by bacteria [Hibst et al. 2001], result in a change of fluorescence intensity, which can be quantified [Atrill and Ashley, 2001]. A digital number, which is presented to the operator in the screen of DIAGNOdent, indicates the amount of fluorescence measured. A higher fluorescence number indicates more demineralisation and consequently a larger lesion. According to a systematic review, in which the performance of DIAGNOdent was studied, its sensitivity and specificity values ranged widely from 0.38-0.95 and 0.24-0.95 respectively for the *in vitro* detection of occlusal enamel caries. According to the *in vitro* studies for detection of occlusal dentinal caries, the sensitivity of DIAGNOdent ranged from 0.19-1.0 and its specificity from 0.52-1. The *in vivo* studies for detection of occlusal dentinal caries showed a sensitivity between 0.73-0.96 and a specificity of 0.63-0.95. [Bader and Shugars, 2004].

The Soprolife system utilizes two types of LEDs that illuminate tooth surfaces in the visible domain, either in the white light or in the blue light region with a narrow band (wavelength 450 nm with a bandwidth of 20 nm) [Tassery et al., 2013]. The camera captures the images in 3 different modes, which are white (day) light, diagnosis and treatment mode. Capturing in white light provides a white light image with a magnification of more than 50 times. The other two modes of the camera work on the principle of autofluorescence. In the diagnostic mode (mode I), the camera uses the visible blue light frequency (wavelength 450 nm) to illuminate the surface of the teeth and provides an anatomic image overlay of the green fluorescence image on the "white light" image. This green fluorescence is considered as an indicator of healthy dental tissues, while carious lesions can be detected by variation in the autofluorescence of the tissues in relation to a healthy area of the same tooth, such as red and black areas on the fluorescence photo. In the treatment mode (mode II), the camera illuminates with increased red wavelengths and decreased blue ones. The red fluorescence, which is captured, is considered as an indicator between infected and affected dentine

[Terrer et al., 2009]. Soprolife diagnostic mode I shows *in vitro* a sensitivity of 0.82 and specificity of 0.86 in detecting dentine caries compared to histology [Gomez et al., 2013].

Photographic images have been used in dentistry in a variety of ways. However, there are very few studies in the literature that have investigated the use of intraoral images and caries diagnosis. In a study of Boye et al. [2012] the photographic assessment method used had a median sensitivity of 81% and a median specificity of 82%, compared to histology, while the visual examination had a lower sensitivity (65%) and a similar specificity (82%).

The aims of the present study were the following.

1. To assess the inter-examiner reliability of ICDAS and Soprolife computer images using 5 examiners.
2. To investigate *in vivo* the validity of the Soprolife fluorescence intraoral camera and DIAGNOdent pen in examining occlusal surfaces with early carious lesions using the ICDAS as the reference score.

## Materials and methods

### Participants

High caries risk children (3-12 years old) who attended the clinic for a regular follow-up were examined for the presence of occlusal surfaces with early carious lesions. Uncooperative or anxious children who required behaviour management techniques were excluded from the study. Also children with deciduous molar hypomineralisation or molar incisor hypomineralisation or with the presence of hypoplastic pits, sound restorations and frank occlusion cavitation, were excluded. A total of 20 patients with small occlusal carious lesions extending into the enamel and dentine were included in the study. Finally, 37 occlusal surfaces (13 primary molars and 24 permanent molars) were examined according to the protocol described below.

### Clinical procedure

Subjects were positioned in a dental unit with operating light illumination. Thirty-seven occlusal surfaces of primary and permanent teeth were examined *in vivo* using DIAGNOdent pen and Soprolife fluorescence intraoral camera. Every examined tooth was cleaned with a rotating bristle brush and a pumice/water slurry prior to examination for the removal of plaque. Then, it was isolated using cotton rolls or cofferdam (if a sealant or preventive resin restoration had been planned), slightly dried, and visually inspected using a plane buccal mirror.

The Diagnodent pen with a tip for occlusal surfaces was calibrated according to manufacturer's instructions so that the reference value appeared in the display. The calibration was done only when the displayed value differed from the reference value. Then the pen was

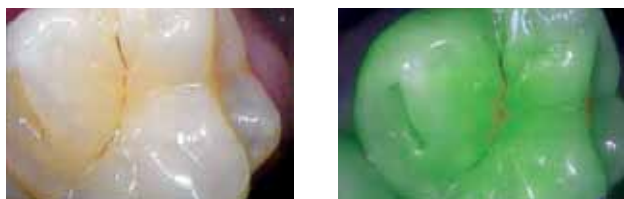

FIG. 1 Tooth 27: white light and fluorescence photo. Mean ICDAS: 1; Soprolife mean score: enamel caries; Diagnodent value: 7.

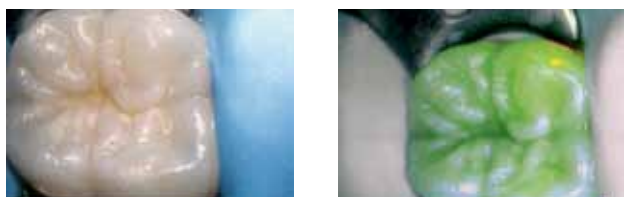


FIG. 2 Tooth 46: white light and fluorescence photo. Mean ICDAS 2; Soprolife mean score: sound; Diagnodent value: 25.

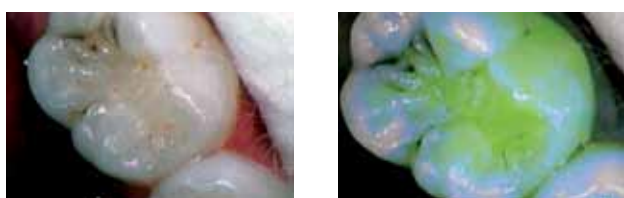

FIG. 3 Tooth 75: white light and fluorescence photo. Mean ICDAS 3; Soprolife mean score: enamel caries; Diagnodent value: 23.

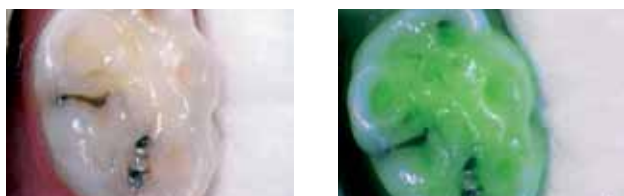

FIG. 4 Tooth 75: white light and fluorescence photo. Mean ICDAS: 4; Soprolife mean scores: dentine lesions; Diagnodent value: 28.

individually adjusted to the patient by applying the probe to a healthy side of a tooth and the occlusal surface of the tooth was scanned by moving the instrument in all directions, without applying pressure. The maximum observed value was recorded.

Finally, one white light picture and one fluorescence image in (diagnostic) mode I of every occlusal surface were taken with the Soprolife camera (Fig. 1-4).

### Ex vivo procedure

The white light photos were evaluated by 5 dentists, using ICDAS system (Table 1), who received a short online training programme in the use of the ICDAS

ICDAS scores	Clinical assessment
0	sound tooth
1	first visual change in enamel after prolonged air drying (>5sec)
2	distinct visual change in enamel
3	localised enamel breakdown
4	underlying dark shadow from dentine
5	distinct cavity with visible dentine
6	extensive distinct cavity with visible dentine

TABLE 1 ICDAS codes.

system (ICDAS.org). After 1week, the fluorescence photos were scored as sound, enamel or dentine caries. The examiners had been trained for the scoring of caries on the fluorescent images with example images. Sound surfaces with Soprolife were the surfaces which showed only green fluorescence.

All the data were entered in a spreadsheet, checked, organised and arranged for analysis using IBM SPSS Statistics version 21.

## Results

### Statistical analysis

The mean ICDAS scores on white light images of the 5 examiners were calculated and then the number of the nearest ICDAS score was given.

Intraclass correlation coefficient was used to measure the inter-examiner agreement of the ICDAS scores and the scores of fluorescence photos of 5 examiners.

The mean of the Soprolife fluorescence images was calculated taking into account the score that was given by most examiners (four out of five).

Cut-off values were calculated for ICDAS, Diagnodent pen values and Soprolife to distinguish sound surfaces and enamel caries from dentinal caries. Sound surfaces (ICDAS 0) and enamel caries (ICDAS 1 and 2) can be protected and the carious process can be easily halted whereas surfaces with ICDAS scores 3 and higher are more extended lesions which require intervention or more invasive treatment. For this reason, ICDAS scores 0, 1, 2 were considered as non dentine lesions, whereas ICDAS scores 3, 4, 5 were considered dentine lesions. DIAGNodent pen values  $\geq 25$  were considered dentine lesions [Lussi et al., 2003] and values  $\leq 24$  as no lesions. Finally, Soprolife scores: sound lesions and enamel lesions were considered no lesions, more advanced lesions were scored as dentine lesions (Table 2). The reference standard for

Cut-offs	Non-dentine caries (Number of occlusal surfaces)			Dentine caries (Number of occlusal surfaces)			
	0	1	2	3	4	5	6
ICDAS (mean scores)	0	3	13	16	5	0	0
Soprolife	Sound	Enamel caries		9			
	4	24					
Diagnodent (values)	0-24			>25			
	21			16			

TABLE 2 Number of occlusal surfaces detected with different methods.

the analysis of sensitivity and specificity of Soprolife and DIAGNOdent was the mean ICDAS scores of 5 examiners at dentine cut-off level.

## Results

The examiners scored on computer screens' white light photos 16 occlusal surfaces as non-dentine caries and 21 surfaces as dentine caries, using ICDAS. There were no occlusal surfaces with mean ICDAS 0, 5 and 6.

On the fluorescence photos the examiners scored 28 surfaces as non-dentine caries and 9 surfaces as dentine caries.

With the clinical examination using Diagnodent, 21 occlusal surfaces had a value below 24 which indicates a healthy tooth substance or an initial demineralisation and 16 surfaces had a value above 25 which indicates a strong demineralisation (Table 2). Figures 1-4 show 4 occlusal surfaces on white light and fluorescence photos, with ICDAS mean scores 1-4. The inter-examiner reliability (ICC) using the ICDAS system on white light photographs for average measures was 0.70 (95% CI: 0.51-0.83). The inter-examiner reliability (ICC) of Soprolife was 0.72 (95% CI: 0.55-0.84) (Table 4).

The sensitivity of Soprolife was 0.43 (95% CI: 0.23-0.66) and its specificity was 1.0 (95% CI: 0.76-1.0) compared to ICDAS. The sensitivity of DIAGNOdent was 0.62 (95% CI: 0.39-0.81) and its specificity was 0.81 (95% CI: 0.54-0.95) compared to ICDAS (Table 3).

## Discussion

We conducted a small-scale study using young children at high caries risk, because we were interested

	Sensitivity (95% CI)	Specificity (95% CI)
Soprolife	0.43 (0.23-0.66)	1.0 (0.76-1.0)
Diagnodent	0.62 (0.39-0.81)	0.81 (0.54-0.95)

TABLE 3 Sensitivity and Specificity of Soprolife and Diagnodent, compared to ICDAS.

	ICC (95%CI)
ICDAS	0.70 (0.51-0.83)
Soprolife	0.72 (0.55-0.84)

TABLE 4 The inter-examiner reliability for ICDAS and Soprolife is determined for an average of 5 evaluations..

in examining promising newly developed different diagnosis systems. Especially, since the validation of use of intra-oral cameras on very young children has not been firmly established.

A common drawback of validation studies on diagnostic systems is the lack of a gold standard. In this study we chose ICDAS, because it has such a broad acceptance base. However when a system would perform better than ICDAS, the specificity of the new method would go down, while in reality the system detection limit may be more sensitive. A proper ex vivo study in which the teeth are first examined in the mouth and later are exfoliated or extracted for orthodontic reasons can be cut for histology and this can serve as a gold standard. Until then newly developed methods can only prove to be equal to the eye in sensitivity.

According to our results, the Soprolife fluorescence intraoral camera could correctly detect 43% of the carious lesions among all the carious surfaces and 100% of the real sound surfaces, when compared to ICDAS. Gomez et al. [2013], in an *in vitro* study, found high sensitivity (0.82) and specificity (0.86) for Soprolife in mode I in detecting occlusal dental lesions. The difference in sensitivity in the two studies can be attributed to the different methodology of each study. Gomez et al. examined 112 permanent molars and premolars with Soprolife mode I, green fluorescence images were captured using an algorithm previously reported, and compared with histology (dentine level demineralization extending from the outer third of dentine to the inner third of dentine was defined as disease positive). We examined 37 occlusal surfaces using Soprolife mode I which were evaluated by 5 examiners and were compared to ICDAS scores.

DIAGNOdent showed a moderate sensitivity of 62% and a high specificity of 81% in detecting early caries

lesions. The wide range of sensitivity and specificity which is presented in different studies [Matos et al., 2011; Terrer et al., 2012; Kouchajij, 2012], can be attributed to the different sample, reference standard, methodology and the different cut-off. Matos et al. (2011) in an *in vivo* study including 407 primary molars, used the value 34 as cut-off to differentiate between sound and dentine caries lesions and found a sensitivity of 0.95-1.00, compared with ICDAS. Similar differences were observed in the other studies.

The ICDAS scale was used as a reference standard as it is a well-developed, widely used international system which shows reproducibility, validity and diagnostic accuracy for the detection of occlusal caries at varying stages of the diseases [Shoab et al., 2009; Diniz et al., 2009; Jablonski-Momeni et al., 2008]. Our study showed that the ICDAS system has a satisfactory inter-examiner reliability (0.70) for average measures in the examination of occlusal lesions using white light images. The inter-examiner agreement could be higher if the examiners had received more training and if the teeth had been examined visually and not via white light photographs. On the photographs, most of the teeth (if not all) were dried, whereas during visual examination the teeth can be observed wet or dried, so ICDAS score 1 and 2 can be more easily differentiated.

Soprolife showed an inter-examiner reliability (0.72) slightly higher than ICDAS. This can be attributed to the fact that the examiners had to classify the fluorescence photos using a 3-score scale (sound, enamel caries or dentine caries) whereas they classified white photos using the 5-score ICDAS scale. In addition, the short training of the 5 examiners in distinguishing between the different fluorescence shades such as green, black, red and grey might have influenced the inter-examiner agreement. The examiners found 4 sound surfaces on Soprolife fluorescence images whereas they found no sound surfaces (ICDAS score 0) on white light images. This happens because, although these surfaces may show a visual change in enamel on white light images, they show green fluorescence on the fluorescence images which is an indicator of healthy surface.

## Conclusion

A short training of dentists in the use of the ICDAS system resulted in satisfactory inter-examiner reliability for the analysis of occlusal lesions on white light images.

Soprolife and Diagnodent do not contribute to a better detection of early carious lesions when compared to ICDAS.

To conclude, Soprolife and Diagnodent do not improve the detection of early carious lesions as they show a low to moderate sensitivity but they are of help in preventing a false diagnosis of sound surfaces as carious, as they show high specificity. In a low caries risk population, these fluorescence methods can be useful in preventing over-treatment.

## References

- › Attrill DC, Ashley PC. Occlusal caries detection in primary teeth: a comparison of DIAGNOdent with conventional methods. *Br Dent J* 2001 Apr 28;190(8): 440-443.
- › Bader JD, Shugars DA. A systematic review of the performance of a laser fluorescence device for detecting caries. *J Am Dent Assoc* 2004 Oct;135(10):1413-26.
- › Boye U, Walsh T, Pretty IA, Tickle M. Comparison of photographic and visual assessment of occlusal caries with histology as the reference standard. *BMC Oral Health* 2012 Apr; 12: 10. doi: 10.1186/1472-6831-12-10.
- › Chong MJ, Seow WK, Purdie DM, Cheng E, Wan V. Visual-tactile examination compared with conventional radiography, digital radiography and Diagnodent in the diagnosis of occlusal occult caries in extracted premolars. *Pediatr Dent* 2003 Jul-Aug;25(4):341-9.
- › Diniz MB, Rodrigues JA, Hug I, Cordeiro Rde C, Lussi A. Reproducibility and accuracy of ICDAS-II for occlusal caries detection. *Community Dent Oral Epidemiol* 2009 Oct; 37(5):399-404.
- › Featherstone JD. Caries detection and prevention with laser energy. *Dent Clin North Am* 2000 Oct;44(4), 955-969.
- › Gomez J, Zakian C, Salsone S, Pinto SC, Taylor A, Pretty IA, Ellwood R. In vitro performance of different methods in detecting occlusal caries lesions. *J Dent* 2013 Feb; 41(2):180-186.
- › Hibst R, Paulus R, Lussi A. Detection of occlusal caries by laser fluorescence: basic and clinical investigations. *Med Laser Appl* 2001; 16 :205-213.
- › Jablonski-Momeni A, Stachniss V, Ricketts DN et al. Reproducibility and accuracy of the ICDAS-II for detection of occlusal caries in vitro. *Caries Res* 2008;42(2):79-87.
- › Kamburoglu K, Kolsuz E, Murat S Yüksel S, Ozen T. Proximal caries detection accuracy using intraoral bitewing radiography, extraoral bitewing radiography and panoramic radiography. *Dentomaxillofac Radiol* 2012 Sep;41(6):450-9.
- › Kouchaji C. Comparison between a laser fluorescence device and visual examination in the detection of occlusal caries in children. *Saudi Dent J* 2012 Jul; 24(3-4), 169-174.
- › Matos R, Novaes TF, Braga MM, Siqueira WL, Duarte DA, Mendes FM. Clinical performance of two fluorescence-based methods in detecting occlusal caries lesions in primary teeth. *Caries Res* 2011;45(3):294-302.
- › Lussi A. Validity of diagnostic and treatment decisions of fissure caries. *Caries Res* 1991; 25(4): 296-303.
- › Shoab L, Beery C, Ricketts DN, Nugent ZJ. Validity and reproducibility of ICDAS II in primary teeth. *Caries Res* 2009;43(6):442-448.
- › Tassery H, Levallois B, Terrer E, Manton DJ, Otsuki M, Koubi S, Gugnani N, Panayotov I, Jacquot B, Cuisinier F, Rechmann P. Use of new minimum intervention dentistry technologies in caries management. *Aust Dent J* 2013 Jun;58 Suppl 1:40-59.
- › Terrer E, Koubi S, Dionne A, Weisrock G, Sarraquigne C, Mazuir A, Tassery H. A new concept in restorative dentistry: light-induced fluorescence evaluator for diagnosis and treatment. Part 1: Diagnosis and treatment of initial occlusal caries. *J Contemp Dent Pract* 2009 Nov 1;10(6):E086-94.