

D. Cassi, A. Di Blasio, M. Gandolfini

Section of Orthodontics, University Dental Center,
S.Bi.Bi.T. Department of Biomedical, Biotechnological and
Translational Sciences, University of Parma, Parma, Italy

e-mail: diana.cassi@unipr.it

Determination of vertical dimension in prosthodontic rehabilitation of a growing patient with severe oligodontia

ABSTRACT

Case report This report describes the oral rehabilitation of a young boy with severe oligodontia of primary dentition and complete anodontia of permanent dentition, treated by complete maxillary and partial mandibular removable dentures. Since the determination of a proper occlusal vertical dimension in paediatric patients is often difficult, treatment was achieved by means of a multidisciplinary approach involving conventional prosthodontic principles combined with cephalometric analysis and growth prediction. After a follow-up of two years a second lateral cephalogram was taken to evaluate the developmental changes in craniofacial morphology and the superimpositions method was performed, showing an improvement of both sagittal and vertical relationship between basal bones. In this case, the early prosthetic treatment resulted in enhanced aesthetics and masticatory function as well as skeletal growth changes.

Keywords Anodontia, lower facial height; Early prosthodontic rehabilitation; Non syndromic oligodontia.

Introduction

Oligodontia is a developmental dental anomaly, characterised by the congenital absence of more than six permanent teeth except the third molars. It is either an isolated trait or part of a syndrome [Polder, 2004].

Children with hypodontia or anodontia show distinctive dentofacial characteristics including maxillary retrusion due to sagittally underdeveloped maxilla, forward-upward displacement of the mandible and collapsed lower anterior facial height [Bondarets, 2000; Chung, 2000; Ferrario, 2004; Lisson 2005; Creton, 2010]. Oral rehabilitation of young children either with partial or complete anodontia has been recommended to improve both sagittal and vertical skeletal relationships during craniofacial growth and development as well as to provide improvements in aesthetics, speech, masticatory efficiency and muscular function [Nomura, 1993; Fanchi, 1998; Sasaki, 2007].

The authors report a case of a 8 years and 9 months old boy presenting severe hypodontia with only primary mandibular second molars, who was treated with a complete maxillary denture and a partial removable mandibular denture. The reduced vertical dimension of the occlusion was restored by means of a conventional approach including aesthetic, phonetics, freeway space, swallowing, combined with cephalometric analysis.

Case report

A boy, aged 8 years and 9 months, was referred to the Dental School Department of Orthodontics of Parma University, Parma (Italy) for evaluation and management of his dentofacial conditions. The child showed complete anodontia of permanent dentition and severe hypodontia of primary dentition, even though he did not exhibit any typical features of ectodermal dysplasia. The information collected during the initial interview revealed no family history of this anomaly.

In the profile view the patient showed reduced vertical dimension of the lower third of the face, a tendency to Class III malocclusion with everted lips, protruded chin and generally his face had a more "aged" appearance (Fig. 1). Clinical oral examination revealed no teeth in the maxilla and only primary second molars in the mandible; the alveolar bone structures were underdeveloped with poorly formed alveolar ridges (Fig. 2, 3). Radiographic examination confirmed the clinical findings, and no unerupted teeth were detected (Fig. 4).

Although the hypotonicity of both the peri-oral and masticatory muscles together with the almost complete

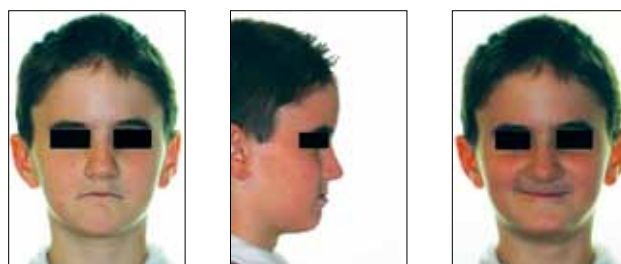

FIG. 1 Facial view and profile of the patient without dentures.

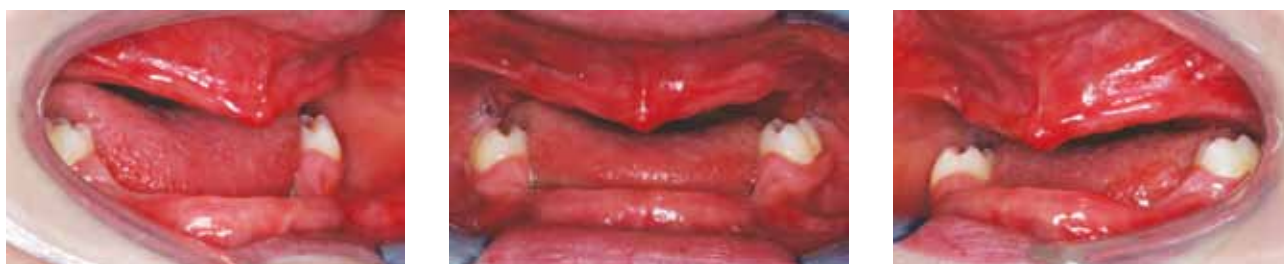

FIG. 2 Intraoral view showing the complete absence of teeth in the maxilla and the presence of only primary second molars in the mandible.

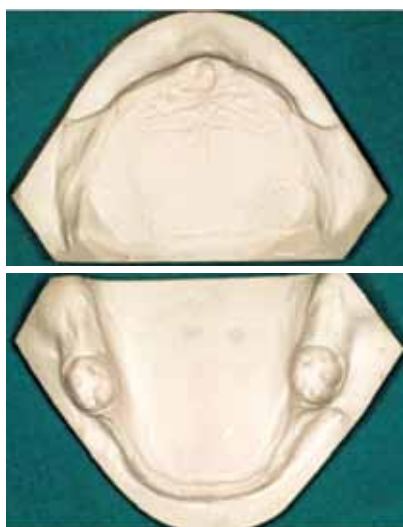


FIG. 3 Dental casts showing underdeveloped maxillary and mandibular ridges.

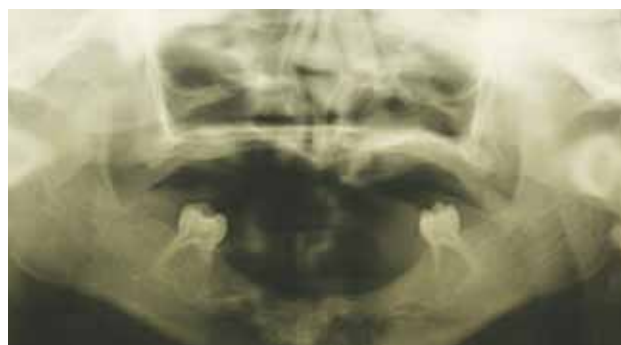

FIG. 4 Panoramic radiograph showing no unerupted teeth.

absence of teeth, the boy fortunately did not develop relevant speech and masticatory difficulties.

The patient was diagnosed with nonsyndromic oligontia (severe partial anodontia) and had been already treated by previous specialists with a maxillary complete denture and a mandibular removable partial denture almost 2 years prior. The dentures had to be remade due to the growth of the jawbones and a craniofacial evaluation was performed by means of cephalometric analysis in order to establish a correct vertical dimension of occlusion and mandibular posture.

A first lateral cephalometric radiograph was obtained in centric occlusion with the patient wearing the old dentures, positioned in a cephalostat and oriented to the Frankfort horizontal plane. The cephalometric radiograph was analysed according to the landmarks shown in Figure 5, and Ricketts' cephalometric analysis was performed in order to evaluate growth changes in skeletal structures based on linear and angular measurement from the lateral cephalogram [Ricketts, 1961]. The patient's values, compared with the norm, are reported in Table 1. The data confirm the clinical diagnosis of Class III short face skeletal relationship: the facial axis shows an unfavourable inclination in relation to the cranial base and indicates an upward and forward direction of mandibular growth; on the sagittal plane the chin is in a forward position and the maxilla is retrognathic, thus leading to a reduced convexity of the face. Angular measurements for vertical relationship between the palatal plane, parallel to the Frankfort horizontal plane, and the mandible

show a significant reduction of the lower facial height. Therefore, the lower facial height angle is compared to an ideal value found out by the following arithmetic formula, proposed by Ricketts [1981]:

Ideal Lower Facial Height = $58 - [(Facial\ Axis - Mandibular\ Plane) / 5]$.

According to the authors, this formula could identify a proper value of the lower facial height, in relation to the

Cephalometric measurements	Value for patient	Norm at age 9
Direction of facial development		
Facial axis (Pt-Gn to Ba-N)	98°	90°±3°
Sagittal relationship		
Maxillary depth (N-A to FH)	84°	90°±3°
Facial angle (N-Pg to FH)	91°	85°
Maxillary convexity (A to N-Pg)	-7 mm	3.1 mm
Vertical relationship		
Palatal plane (ANS-PNS to FH)	0°	0°+2.5°
Mandibular plane (Go-Me to FH)	23°	26°
Lower facial height (ANS-Xi- Pm)	40°	46°±3°
Ideal lower facial height	43°	58-[(facial axis-mandibular plane)/5]
Internal form of the mandible		
Mandibular arc (Dc-Xi to Xi-Pm)	31°	26°±4°
Profile		
Upper lip to E-Plane	-7 mm	0±2 mm
Lower lip to E-Plane	-3 mm	-2±2 mm

TABLE 1 Values for the cephalometric measurements at age of 8 years and 10 months compared with the norm [Ricketts, 1981].

FIG. 5
Ricketts' cephalometric analysis performed on lateral cephalogram at the age of 8 years and 10 months.

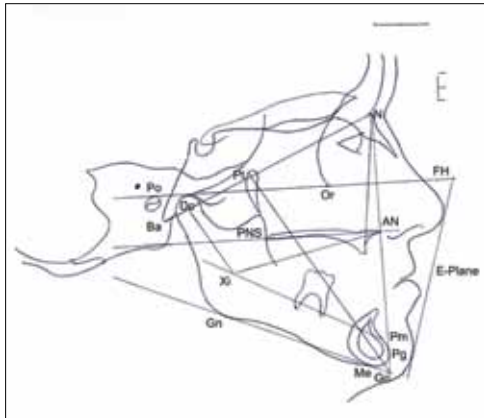
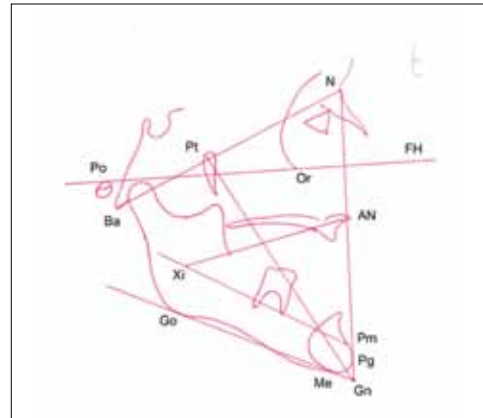


FIG. 6
Visualized Objectives Treatment (V.T.O.) constructed on the lateral cephalogram showing a new mandible position.



craniofacial morphology of the single patient.

The soft tissue analysis shows inversion of the relation between upper and lower lips, being both considerably behind the aesthetic plane (E-Planes), a line from the tip of the nose to the soft tissue Pogonion.

New dentures were fabricated to establish a harmonious craniofacial pattern particularly as far as the vertical and sagittal position of the mandible is concerned. For this reason the determination of the vertical dimension was first based on cephalometric criteria and then checked by means of classical prosthetic principles. "Visualized Treatment Objectives" (VTO) were worked out on the lateral cephalogram (Fig. 6): the angle of the lower facial height was improved from 40° to 43° through a clockwise rotation of the mandible, modifying subsequently all parameters defining mandible posture, such as facial axis, facial plane and mandibular plane. Therefore, the new value for the ideal lower facial height was 44°, being closer to the one chosen in the VTO and suggestive of a proper vertical skeletal relationship (Table 2).

Prosthetic management of the young patient followed the conventional prosthodontic principles [Pigno, 1996; Preti, 2003; Vieira 2007; Vallejo, 2008; Bidra, 2010]. Heavy silicone was used to take some preliminary impressions and make custom trays and later an alginate impression was taken under more favourable conditions. On the master casts acrylic bases with wax rims were made, establishing the maxillomandibular relations decided on the VTO. The new vertical dimension was clinically verified on the patients, with regard to the presence of freeway space, appearance of the lips, occlusal plane relative to the tongue and phonetic tests. Maxillary complete and mandibular removable partial dentures were fabricated by conventional methods using heat-curing acrylic resin and steel retainers on the first lower molars. Prosthetic teeth were chosen to achieve an age-appropriate appearance for the child with a diastema between upper incisors. After the final insertion, hygiene instructions for the dentures were given to the patient and his parents; periodic recalls were prescribed, approximately once every 3 months, in order to make small adjustments and modifications to the prosthesis, especially the lower one. The patient adapted well to the dentures and wore them

Cephalometric measurements	Patient	VTO
Facial axis	98°	95°
Mandibular plane	23°	25°
Lower facial height	40°	43°
Ideal lower facial height	43°	44°

TABLE 2
Patient's parameters defining mandible posture compared with the VTO values.

on a full-time basis.

A second lateral cephalogram with denture in occlusion was taken after 2 years; Ricketts' cephalometric analysis and superimposition methods were performed (Fig. 7, 8) in order to evaluate skeletal and soft tissue changes, resulting from growth and correction of the lower facial height. The increase in vertical dimension of the lower third of the face produced a clockwise rotation of the mandible and a more retruded chin, improving the Class III skeletal relationship. Superimposition methods demonstrated that craniofacial growth was progressing in a normal way. The first superimposition (Basion-Nasion registered at CC point) was performed to evaluate the direction of chin growth: the facial axis shows a more favourable inclination in relation to the cranial base and indicates a quite normal direction of mandibular growth. The second superimposition (Basion-Nasion registered at Nasion point) established the direction of growth of the maxilla (point A). In the patient, the Basion-Nasion Point A angle shows a slight decrease, thus confirming the reduction of anterior growth of the maxilla, even though it is difficult to determine whether this lack of growth was due to the absence of teeth or to an effect of the prosthetic replacement of the teeth.

The placement of new dentures improved the soft tissues aesthetics, harmonizing the lips position related to the nose and the chin and evenness of nasolabial and mentolabial sulcus (Fig. 9, 10).

Discussion

Children with severe oligodontia or anodontia usually present a reduced lower facial height, that is, a deficiency in the vertical dimension. Therefore, one of the major

FIG. 7 Superimposition on line Basion-Nasion with registration at CC point (black line= tracing at the age of 8 years and 10 months; red line= tracing at the age of 10 years and 9 months).

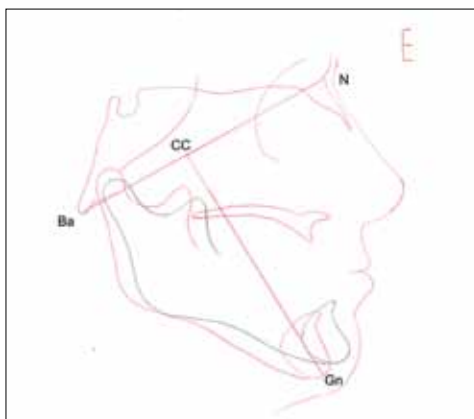
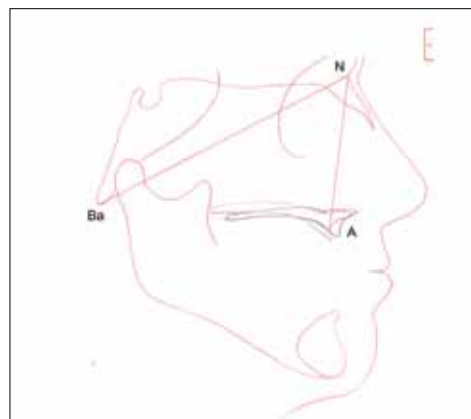


FIG. 8 Superimposition on line Basion-Nasion with registration at Nasion.



problems with early placement of complete dentures in a growing patient is to establish a correct occlusion in the vertical dimension [Imrizalioglu, 2002; Bani, 2010]. In the literature are described many clinical procedures including physiological rest position method combined with aesthetic, phonetic and swallowing examinations [Ramos, 1995, Tarjan, 2005, Bidra, 2010]. The clinically determined occlusal vertical dimension may also be confirmed by cephalogram analysis [Franchi, 1998].

In the present study, we chose the vertical relationship between the maxilla and the mandible by means of a cephalometric parameter such as the ideal lower facial height angle, described by Ricketts, taking into account the individual variation in growth and development. With this procedure, the mandible position is set on a VTO based on the patient lateral cephalogram and the lower facial height angle is increased through a clockwise rotation of the lower jaw until its value becomes closer to the ideal one.

Conclusion

Early placement of dentures in children with severe oligodontia can provide better conditions for growth and development of the orofacial structures. In particular, early correction of collapsed lower anterior facial height, due to forward displacement of the mandible, plays an important role in normalising the function of masticatory and perioral muscles, improving facial aesthetics and consequently affecting the growth pattern of basal bone. Cephalometric evaluation of craniofacial features could represent a diagnostic and therapeutic tool in prosthetic management of growing children with oligodontia.

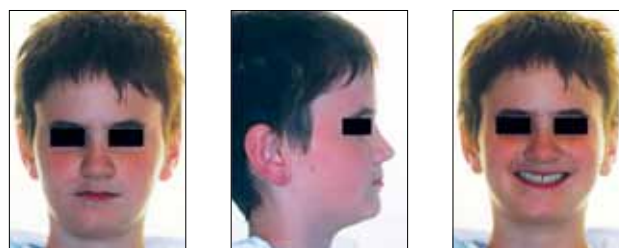

FIG. 9 Facial view and profile of the patient with the new dentures.

References

- > Bani M et al. Ectodermal dysplasia with anodontia: a report of two cases. *Eur J Dent* 2010;4(2):215-222.
- > Bidra AS, Martin JW and Feldman E. Complete denture prosthetics in children with ectodermal dysplasia: review of principles and techniques. *The Compend Contin Educ Dent* 2010;31(6):426-433.
- > Bondarets N, McDonald F. Analysis of the vertical facial form in patients with severe hypodontia. *Am J Phys Anthropol* 2000;111(2):177-184.
- > Chung L-KL, et al. An analysis of the skeletal relationships in a group of young people with hypodontia. *J Orthod* 2000;27(4):315-318.
- > Créton M, et al. Dentofacial characteristics of patients with hypodontia. *Clin Oral Invest* 2010;14(4):467-477.
- > Ferrario VF, et al. Soft-tissue facial areas and volumes in individuals with ectodermal dysplasia: a three-dimensional non invasive assessment. *Am J Med Genet A* 2004;126A(3):253-260.
- > Franchi L, Branchi R and Tollaro I. Craniofacial changes following early prosthetic treatment in a case of hypodontic dysplasia with complete anodontia. *ASDC J Dent Child* 1998; 65(2):116-121.
- > Imrizalioglu P, Uckan S and Haydar SG. Surgical and prosthodontic treatment alternatives for children and adolescent with ectodermal dysplasia: a clinical report. *J Prosthet Dent* 2002;88(6):569-572.
- > Lisson JA and Scholtes S. Investigation of craniofacial morphology in patients with hypodontia. *J Orofac Orthop* 2005;66(3):197-207.
- > Nomura S, et al. Longitudinal study of jaw growth and prosthodontic management in a patient with ectodermal dysplasia and anodontia. *Int J Paediatr Dent* 1993;3(1):29-38.
- > Pigno MA et al. Prosthodontic management of ectodermal dysplasia: a review of the literature. *J Prosthet Dent* 1996;76(5):541-545.
- > Polder BJ et al. A meta-analysis of the prevalence of dental agenesis of permanent teeth. *Community Dent Oral Epidemiol* 2004;32(3):217-226.
- > Preti G. *Riabilitazione protesica*. Torino: UTET; 2003.
- > Ramos Van BS et al. Complete dentures for a child with hypodontic ectodermal dysplasia: a clinical report. *J Prosthet Dent* 1995;74(4):329-331.
- > Ricketts RM. Cephalometric analysis and synthesis. *Angle Orthod* 1961;31(3):141-156.
- > Ricketts RM. Perspectives in the clinical application of cephalometrics. *Angle Orthod* 1981;51(2):115-150.
- > Sasaki Y et al. Craniofacial growth and functional change in oligodontia with ectodermal dysplasia: a case report. *J Oral Rehabil* 2007;34(3):228-235.
- > Tarjan I, Gabris K, Rozsa N. Early prosthetic treatment of patients with ectodermal dysplasia: a clinical report. *J Prosthet Dent* 2005;93(5):419-424.
- > Vallejo A et al. Treatment with removable prosthesis in hypodontic ectodermal dysplasia. A clinical case. *Med Oral Pat Oral Cir Bucal* 2008;13(2):119-123.
- > Vieira KA et al. Prosthodontic treatment of Hypodontic ectodermal dysplasia with complete anodontia: case report. *Quintessence Int* 2007;38(1):75-80.

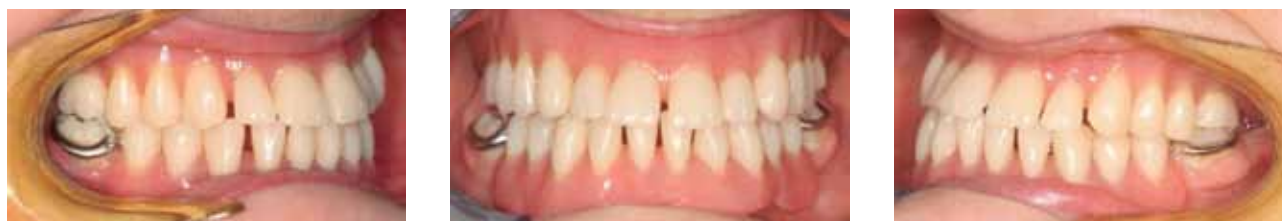

FIG. 10 Intraoral view showing the maxillary complete and mandibular removable partial dentures.